



## PATIENT

Azora Montano

## SPECIES

Canine

## BREED

Australian Cattle Dog  
Mix

## SEX

Female Spayed

## AGE

4Y

## WEIGHT

51

## INTERPRETED BY

Sebastian Schaub, DVM  
Dr. med. vet.  
DipECVDI

## IMAGING PERFORMED BY

Justeen Marquez

## HOSPITAL NAME

Petroglyph Animal  
Hospital

## REFERRING VET

Cassidy Stone

## INVOICE

73392

## DATE

1-20-26

## PRESENTING CLINICAL SIGNS

History:

- Chronic L sided lameness - concern for shoulder or elbow issues

Abnormal PE/Chem/CBC/UA Results: None

## COMPUTED TOMOGRAPHY OF THE ELBOW JOINTS

A high resolution pre- and post-contrast CT study of the elbow joints is provided for review.

## COMPUTED TOMOGRAPHIC FINDINGS

The bony and surrounding soft tissue structures reveal no abnormalities.

Both elbow joints present smooth margins of the periarticular bones. The cranial tip of the medial coronoid process of the left elbow joint has a decreased density. An ill-defined fissure line is seen caudal to the tip of the medial coronoid process of the left elbow joint. An isolated roundish, mineralized body is seen distal to the medial humeral epicondyle.

The tip of the medial coronoid process of the right elbow joint has a homogeneous density.

## COMPUTED TOMOGRAPHIC DIAGNOSIS

- Coronoid disease left elbow joint
- Mild left sided flexor tendinopathy with metaplasia
- Normal right elbow joint

## INTERPRETATION OF THE FINDINGS & FURTHER RECOMMENDATIONS

The hypoattenuating tip of the medial coronoid process of the left elbow joint is highly suggestive for elbow dysplasia – a potential cause for the left front limb lameness. Arthroscopy/arthrotomy would be ideal to revise the elbow joints and remove the osseous fragment/nonvital tip of the medial coronoid process to avoid further damage.



## PATIENT

Azora Montano

## SPECIES

Canine

## BREED

Australian Cattle Dog  
Mix

## SEX

Female Spayed

## AGE

4Y

## WEIGHT

51

## INTERPRETED BY

Sebastian Schaub, DVM  
Dr. med. vet.  
DipECVDI

## IMAGING PERFORMED BY

Justeen Marquez

## HOSPITAL NAME

Petroglyph Animal  
Hospital

## REFERRING VET

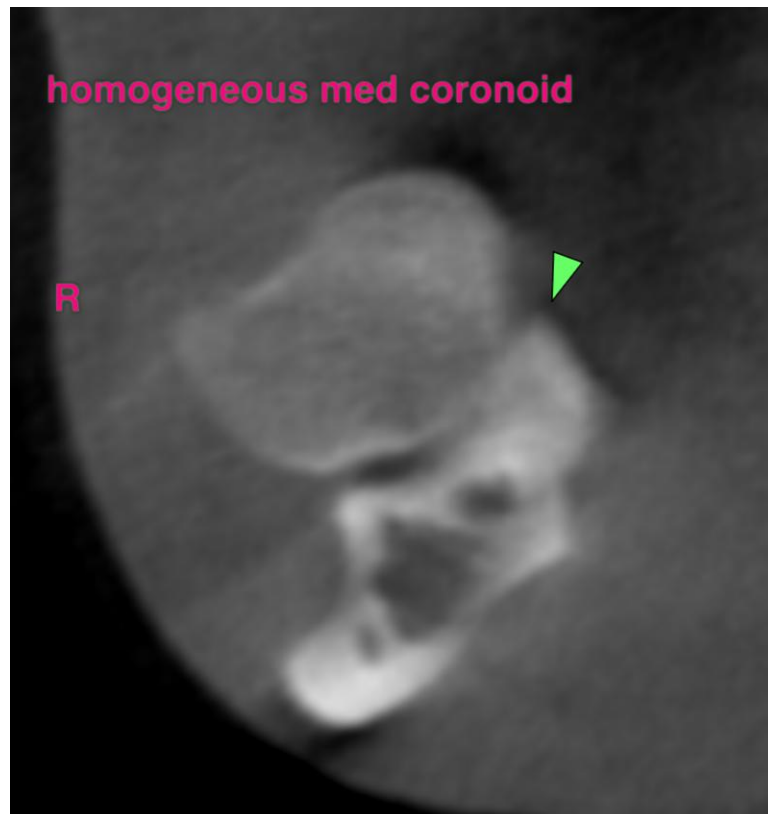
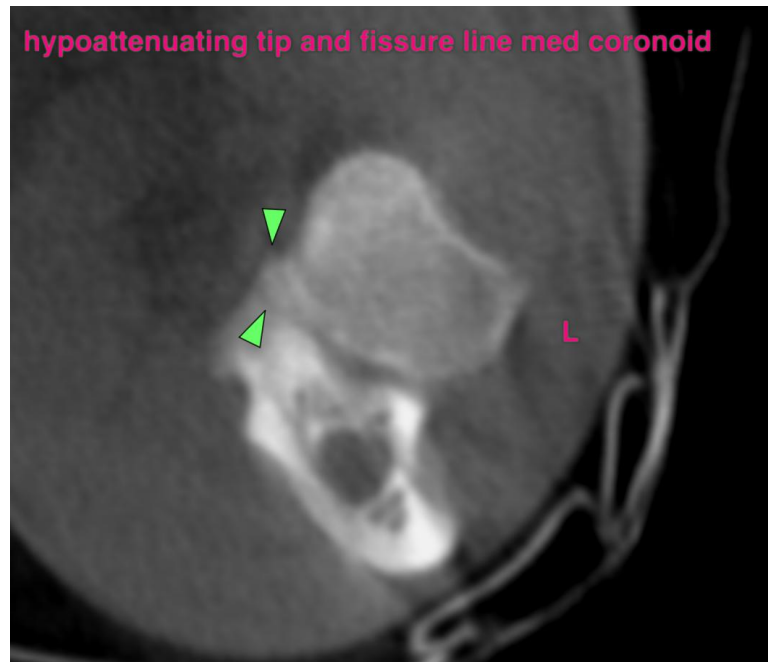
Cassidy Stone

## INVOICE

73392

## DATE

1-20-26





## PATIENT

Azora Montano

## SPECIES

Canine

## BREED

Australian Cattle Dog  
Mix

## SEX

Female Spayed

## AGE

4Y

## WEIGHT

51

## INTERPRETED BY

Sebastian Schaub, DVM  
Dr. med. vet.  
DipECVDI

## IMAGING PERFORMED BY

Justeen Marquez

## HOSPITAL NAME

Petroglyph Animal  
Hospital

## REFERRING VET

Cassidy Stone

## INVOICE

73392

## DATE

1-20-26

The information and recommendations provided are based on the images presented by the referring veterinarian/sonographer. No evaluation can be communicated regarding pathology that was not visible in the image/video clips provided.

Thank you for this referral. If the clinical or image interpretation does not parallel your findings or if I can be of any further assistance please contact me.

**Sebastian Schaub**, Sebastian Schaub, DVM, Dr. med. vet. DipECVDI  
[info@sonopath.com](mailto:info@sonopath.com)