



PATIENT PRESENTING CLINICAL SIGNS

Kona Fox History: On and off lame of left front for some time, but only for very short periods of time. Acutely 3-legged lame after jumping off the couch yesterday.

SPECIES Abnormal PE/Chem/CBC/UA Results: Severe left front muscle atrophy, 4/5 lame left front, very reactive to left foot deep palpation. Minimal swelling and no laxity or defect noted. Remainder of exam is normal.
Canine

RADIOGRAPHIC STUDY OF THE FRONT LIMBS

BREED

Boykin Spaniel A complete set of radiographs of the front limbs is provided for review.

RADIOGRAPHIC FINDINGS

SEX Both shoulder joints present smooth osseous margins and the surrounding soft tissue structures are within normal limits.
Neutered Male

AGE The osseous structures of the left elbow joint present smooth osseous margins. The contour of the medial coronoid process is well-defined and has a homogeneous density. The surrounding soft tissue structures are within normal limits.

12 Years 11 Months The osseous and soft tissue structures of the carpal joints bilaterally present smooth osseous margins and without abnormalities of the surrounding soft tissue structures.

INTERPRETED BY Both front paws present without abnormalities of the osseous structures. The third digit of the left front paw presents with a circumferential homogeneous moderate soft tissue swelling.

Sebastian Schaub,
 DVM Dr. med. vet.
 DipECVDI

RADIOGRAPHIC DIAGNOSIS

- HOSPITAL NAME**
- Soft tissue swelling third digit left front paw
 - Normal shoulder joints
 - Normal left elbow joint
 - Normal carpal joints
- Elizabeth AH

REFERRING VET

Leon Anderson, DVM

INTERPRETATION OF THE FINDINGS & FURTHER RECOMMENDATIONS

The main finding is the soft tissue swelling of the third digit of the left front paw, the osseous structures present without abnormalities. The soft tissue swelling can be a sequela to the trauma. Other potentials would include infection or less likely neoplastic disease.

INVOICE

20707

DATE

1/20/23



PATIENT

Kona Fox

SPECIES

Canine

BREED

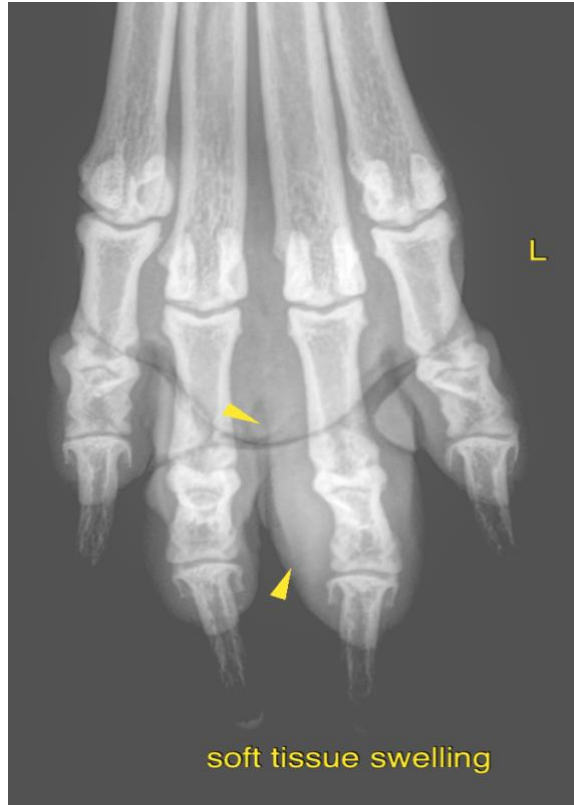
Boykin Spaniel

SEX

Neutered Male

AGE

12 Years 11 Months



INTERPRETED BY

Sebastian Schaub,
DVM Dr. med. vet.
DipECVDI

The information and recommendations provided are based on the images presented by the referring veterinarian/sonographer. No evaluation can be communicated regarding pathology that was not visible in the image/video clips provided.

Thank you for this referral. If the clinical or image interpretation does not parallel your findings or if I can be of any further assistance please contact me.

HOSPITAL NAME

Elizabeth AH

Sebastian Schaub, Sebastian Schaub, DVM, Dr. med. vet. DipECVDI
sebast.schaub@gmail.com

REFERRING VET

Leon Anderson, DVM

INVOICE

20707

DATE

1/20/23