



PATIENT PRESENTING CLINICAL SIGNS

Archie Schneider History: Pet presented today for dental cleaning. Tartar score 3.5/4

COMPUTED TOMOGRAPHIC STUDY OF THE SKULL

SPECIES

Canine

A high resolution plain CT study of the skull is provided for review.

COMPUTED TOMOGRAPHIC FINDINGS

BREED

Goldendoodle

The dentition is complete. The tip of the crown of triadan 204 is absent, exposing the pulp cavity to the dental surface. The pulp cavity of triadan 204 is widened in comparison to the remaining canine teeth. The periodontal space of triadan 204 is mild to moderately widened and the osseous lamella between the alveolar crest of triadan 204 and the nasal cavity is incomplete. The remainder of the dentition present without abnormalities of the periodontal space.

SEX

Male

The nasal cavity presents the expected aerated spaces between thin & even conchae and turbinates with smooth mucosal lining.

AGE

2 Years

COMPUTED TOMOGRAPHIC DIAGNOSIS

- Complicated dental fracture 204 with widened pulp cavity and periodontal granuloma formation and oronasal fistula formation

INTERPRETATION OF THE FINDINGS & FURTHER RECOMMENDATIONS

INTERPRETED BY

Sebastian Schaub,
DVM Dr. med. vet.
DipECVDI

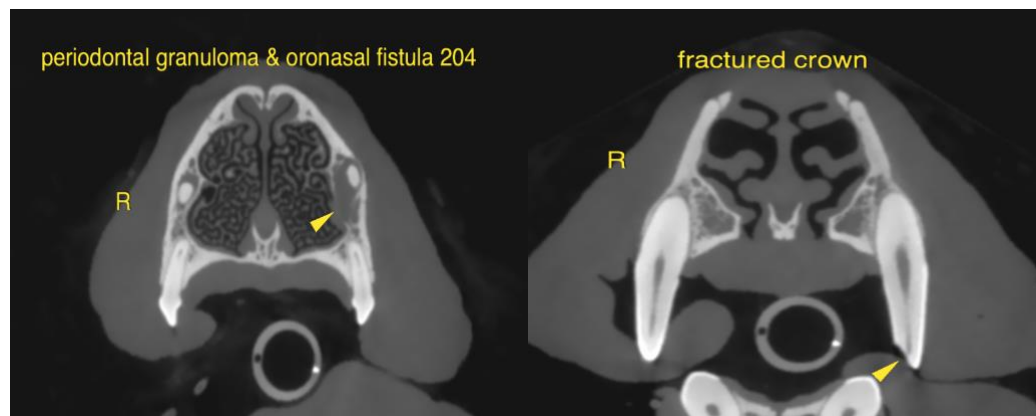
There is evidence of complicated dental fracture 204, the widened pulp cavity indicates that triadan 204 is not vital anymore and there is evidence of periapical granuloma formation. The chances of root canal treatment versus extraction of the respective teeth can be discussed with dentist.

HOSPITAL NAME

Cranberry Holistic PC

REFERRING VET

Dr. Cynthia Maro



INVOICE

20703

The information and recommendations provided are based on the images presented by the referring veterinarian/sonographer. No evaluation can be communicated regarding pathology that was not visible in the image/video clips provided.

DATE

1/20/23



PATIENT

Archie Schneider

Thank you for this referral. If the clinical or image interpretation does not parallel your findings or if I can be of any further assistance please contact me.

SPECIES

Canine

Sebastian Schaub, Sebastian Schaub, DVM, Dr. med. vet. DipECVDI
sebast.schaub@gmail.com

BREED

Goldendoodle

SEX

Male

AGE

2 Years

INTERPRETED BY

Sebastian Schaub,
DVM Dr. med. vet.
DipECVDI

HOSPITAL NAME

Cranberry Holistic PC

REFERRING VET

Dr. Cynthia Maro

INVOICE

20703

DATE

1/20/23