



**PATIENT**

Daisy Emanuele

**PRESENTING CLINICAL SIGNS**

12/30/21 Female intact, presented with a red mass coming out of her vaginal area. Are we going to be able to removed mass with a routine spay? It is involving cervix?  
Abnormal PE/Chem/CBC/UA Results: 12/30/21 Labwork WNL

**SPECIES**

Canine

**COMPUTED TOMOGRAPHY OF THE PELVIS**

A high resolution pre- and post-contrast CT study of the pelvis is provided for review.

**BREED**

Pomeranian

**COMPUTED TOMOGRAPHIC FINDINGS**

The serosal fat presents normal attenuation behavior. There is no evidence of peritoneal effusion or peritonitis.

**SEX**

Female

Both kidneys present within normal limits for size, shape and organ architecture. After contrast administration a bilaterally symmetric and uniform nephro- and pyelogram is noted.

**AGE**

15 Years

The vagina is moderately swollen and presents with a maintained wall layering and longitudinal folding of the vaginal wall – as expected. The region of the cervix is within normal limits. The uterine horns are prominent and post contrast administration, multiple well-defined mural filling defects are seen. In the first post contrast study no mass can be appreciated in the pictured parts of the vagina. In the second study, a polypoid mild hypoattenuating lesion appears to originate from the roof of the region of the vaginal vestibulum, measuring approximately 1.3 cm in diameter.

**INTERPRETED BY**

Sebastian Schaub, DVM  
Dr. med. vet. DipECVDI

The position, delineation, wall and content of the gastrointestinal tract are considered within normal limits throughout.

The bony and surrounding soft tissue structures reveal no abnormalities.

**HOSPITAL NAME**

Taconic Route 202 24  
Hour Veterinary  
Center

**COMPUTED TOMOGRAPHIC DIAGNOSIS**

- Suspect pedunculated vaginal mass
- Generalized hyperplasia of the vagina and uterine horns with intramural cystic lesions

**REFERRING VET**

Dr. Mary Wallace

**INTERPRETATION OF THE FINDINGS & FURTHER RECOMMENDATIONS**

The potentially pedunculated mass appreciated in the second CT study is most consistent with benign vaginal tumor such as leiomyoma, fibroma. The odds for malignant vaginal neoplasm are low – such as leiomyosarcoma.

**INVOICE**

49687

The generalized hyperplasia of the vagina is compatible with the estrous cycle.

Recommend surgical excision of the pedunculated mass – ligating the lesion at the base, by passing a suture loop over the mass up to the base, follow by sharp dissection of the stalk is a feasible technique. The mass will not be removed by ovariectomy.

**DATE**

1-20-22

The cystic endometrial lesions are suggestive for mild glandular cystic endometrial hyperplasia. Ovariectomy is a feasible option for prevention of tumor recurrence.



**PATIENT**

Daisy Emanuele

**SPECIES**

Canine

**BREED**

Pomeranian

**SEX**

Female

**AGE**

15 Years

**INTERPRETED BY**

Sebastian Schaub, DVM  
Dr. med. vet. DipECVDI

**HOSPITAL NAME**

Taconic Route 202 24  
Hour Veterinary  
Center

**REFERRING VET**

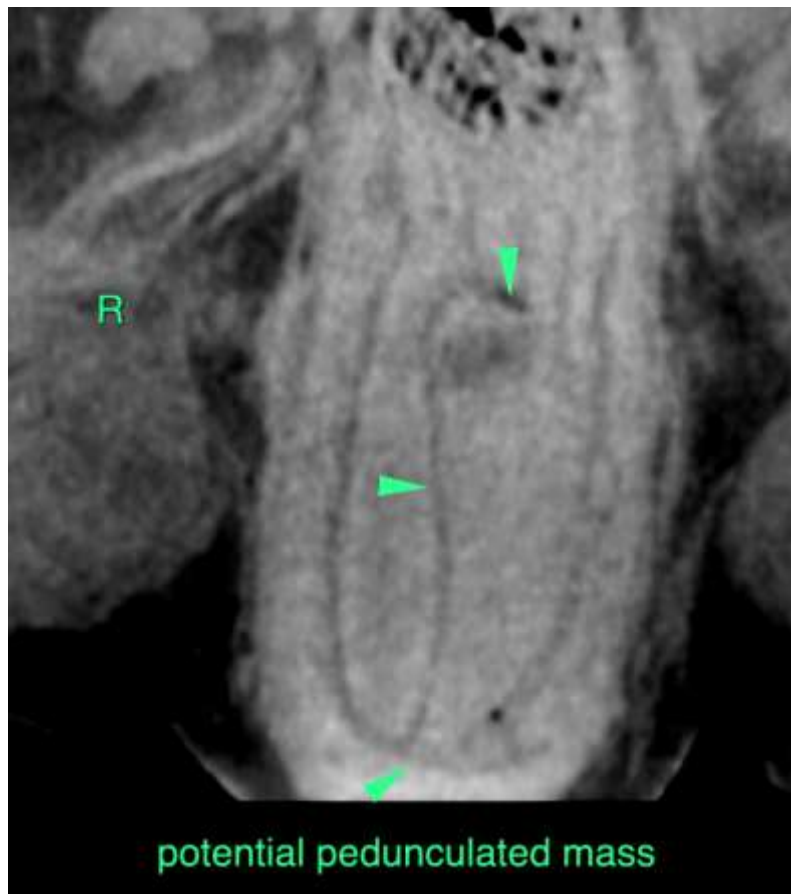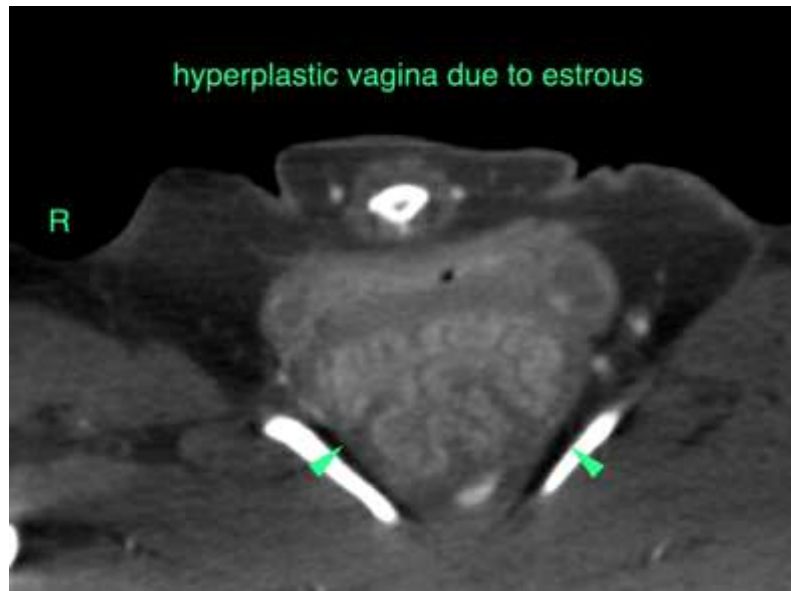Dr. Mary Wallace

**INVOICE**

49687

**DATE**

1-20-22





**PATIENT**

Daisy Emanuele

**SPECIES**

Canine

**BREED**

Pomeranian

**SEX**

Female

**AGE**

15 Years

**INTERPRETED BY**

Sebastian Schaub, DVM  
Dr. med. vet. DipECVDI

**HOSPITAL NAME**

Taconic Route 202 24  
Hour Veterinary  
Center

**REFERRING VET**

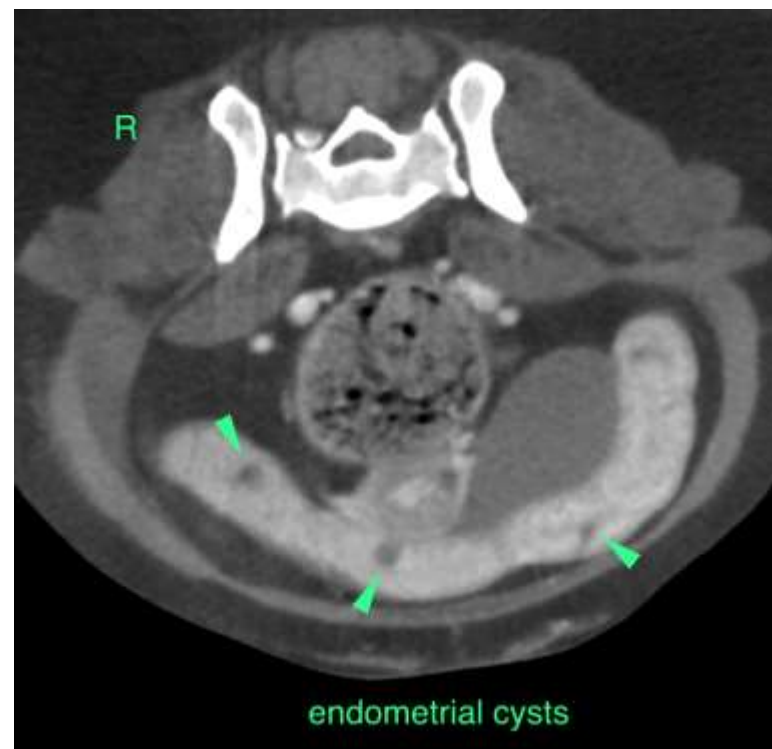
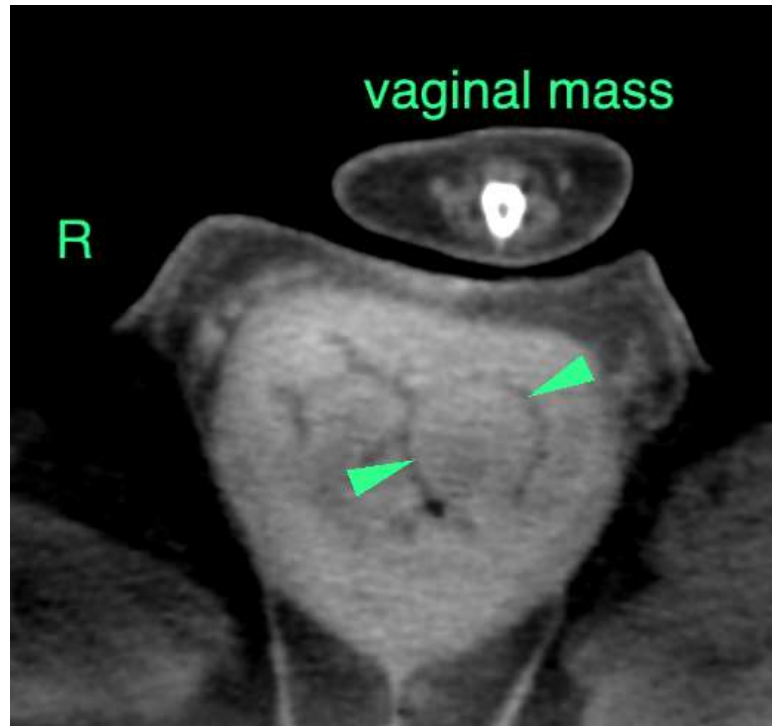
Dr. Mary Wallace

**INVOICE**

49687

**DATE**

1-20-22





**PATIENT**

Daisy Emanuele

The information and recommendations provided are based on the images presented by the referring veterinarian. No evaluation can be communicated regarding pathology that was not visible in the image/video clips provided.

**SPECIES**

Canine

Thank you for this referral. If the clinical or image interpretation does not parallel your findings or if I can be of any further assistance please contact me.

**BREED**

Pomeranian

**Sebastian Schaub**, Sebastian Schaub, DVM, Dr. med. vet. DipECVDI  
sebast.schaub@gmail.com

**SEX**

Female

**AGE**

15 Years

**INTERPRETED BY**

Sebastian Schaub, DVM  
Dr. med. vet. DipECVDI

**HOSPITAL NAME**

Taconic Route 202 24  
Hour Veterinary  
Center

**REFERRING VET**

Dr. Mary Wallace

**INVOICE**

49687

**DATE**

1-20-22