



**PATIENT**

Minho Shi

**PRESENTING CLINICAL SIGNS**

Severe cervical neck pain Trembling

**SPECIES**

Canine

**RADIOGRAPHIC STUDY OF THE CERVICAL SPINE**

A lateral projection of the cervical spine is provided for review.

**RADIOGRAPHIC FINDINGS**

The intervertebral disc space C5/C6 is moderately narrowed.

**BREED**

Jindo Mix

The remainder of the osseous structures of the cervical spine and the surrounding soft tissue structures of the neck are within normal limits.

**RADIOGRAPHIC DIAGNOSIS**

**SEX**

Male/N

- Discopathy C5/C6

**INTERPRETATION OF THE FINDINGS & FURTHER RECOMMENDATIONS**

The narrowed intervertebral disc space C5/C6 indicates discopathy that might be associated with compressive myelopathy as source for the presenting clinical signs. Depending on the development of clinical signs under empirical management, cross-sectional imaging is recommended for further workup and potential surgical planning.

**AGE**

3 Years

**INTERPRETED BY**

Sebastian Schaub, DVM  
Dr. med. vet. DipECVDI

**HOSPITAL NAME**

New Bridge  
Veterinary Practice

**REFERRING VET**

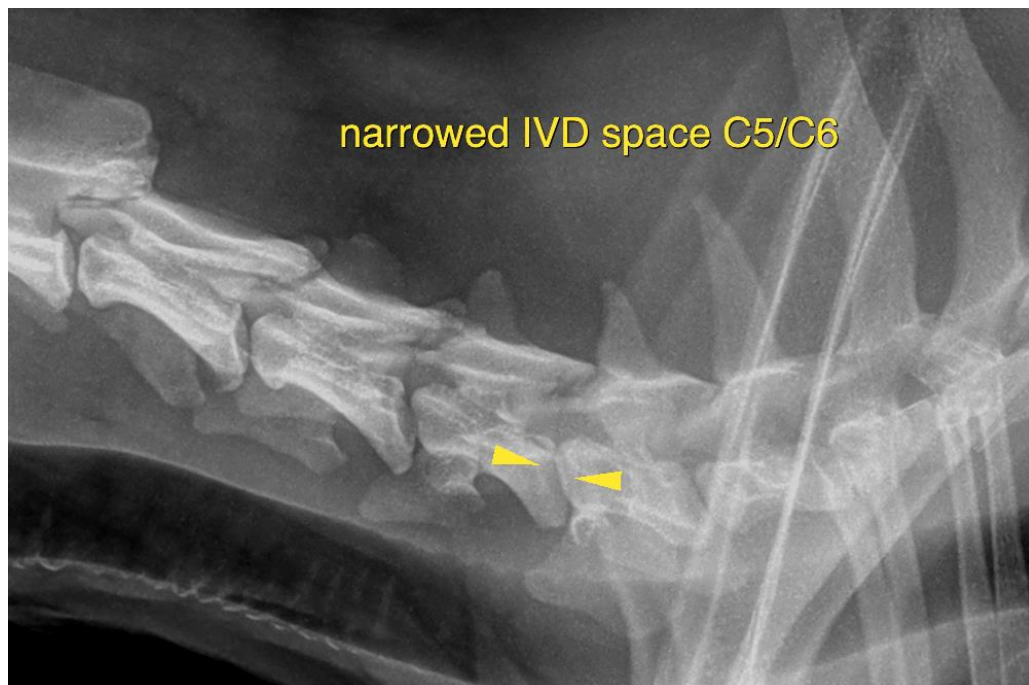
Dr. Abina Glennon

**INVOICE**

55922

**DATE**

1-2-23





**PATIENT**

Minho Shi

The information and recommendations provided are based on the images presented by the referring veterinarian/sonographer. No evaluation can be communicated regarding pathology that was not visible in the image/video clips provided.

**SPECIES**

Canine

Thank you for this referral. If the clinical or image interpretation does not parallel your findings or if I can be of any further assistance please contact me.

**BREED**

Jindo Mix

**Sebastian Schaub**, Sebastian Schaub, DVM, Dr. med. vet. DipECVDI  
sebast.schaub@gmail.com

**SEX**

Male/N

**AGE**

3 Years

**INTERPRETED BY**

Sebastian Schaub, DVM  
Dr. med. vet. DipECVDI

**HOSPITAL NAME**

New Bridge  
Veterinary Practice

**REFERRING VET**

Dr. Abina Glennon

**INVOICE**

55922

**DATE**

1-2-23