



PATIENT PRESENTING CLINICAL SIGNS

Cici Echevarria

History: Cici is a 11yo SF Yorkshire presented today for an exam because she has been loosing balance when walking. On wednesday O's mom was walking Cici, when she lost balance and fell. O noticed that she has been wlkng slowly and with her head low. Also she is not going down from the bed or up to the couch. O has stairs to go up to the bed, p goes up the stairs but once she has to jump to the bed she won't do it. C/S/V/D: occasional cough due to collapsed trachea E/D/U/D: wnl Diet: did not ask FAS Score: 1. very nervous Current Medications (dose and frequency): hycodan as needed for cough Heartworm Prevention / Flea Prevention: simparica trio Known Allergies and Medical Conditions: collapsing trachea. insulinoma Microchip ID: 985112000366849 / No microchip

SPECIES

Canine

BREED

Yorkshire Terrier

SEX

SF

AGE

11 Years, 3 Months

INTERPRETED BY

Sebastian Schaub, DVM
Dr. med. vet. DipECVDI

RADIOGRAPHIC STUDY OF THE NECK

Radiographs of the neck in two orthogonal imaging planes are provided for review.

HOSPITAL NAME

DPC Veterinary Hospital

RADIOGRAPHIC FINDINGS

Mild to moderate dorsoventral flattening of the trachea is appreciated.

The intervertebral disc space C3/C4 is mildly narrowed.

REFERRING VET

Dr. White

RADIOGRAPHIC DIAGNOSIS

- Discopathy C3/C4
- History of tracheal collapse

INVOICE

55920

INTERPRETATION OF THE FINDINGS & FURTHER RECOMMENDATIONS

The narrowed intervertebral disc space C3/C4 is indicating discopathy that might or might not be associated with compressive myelopathy as source for the presenting clinical signs. Depending on the development of clinical signs under empirical pain management, cross-sectional imaging is recommended for decision making if surgical decompression would be beneficial.

DATE

1-2-23



PATIENT

Cici Echevarria

SPECIES

Canine

BREED

Yorkshire Terrier

SEX

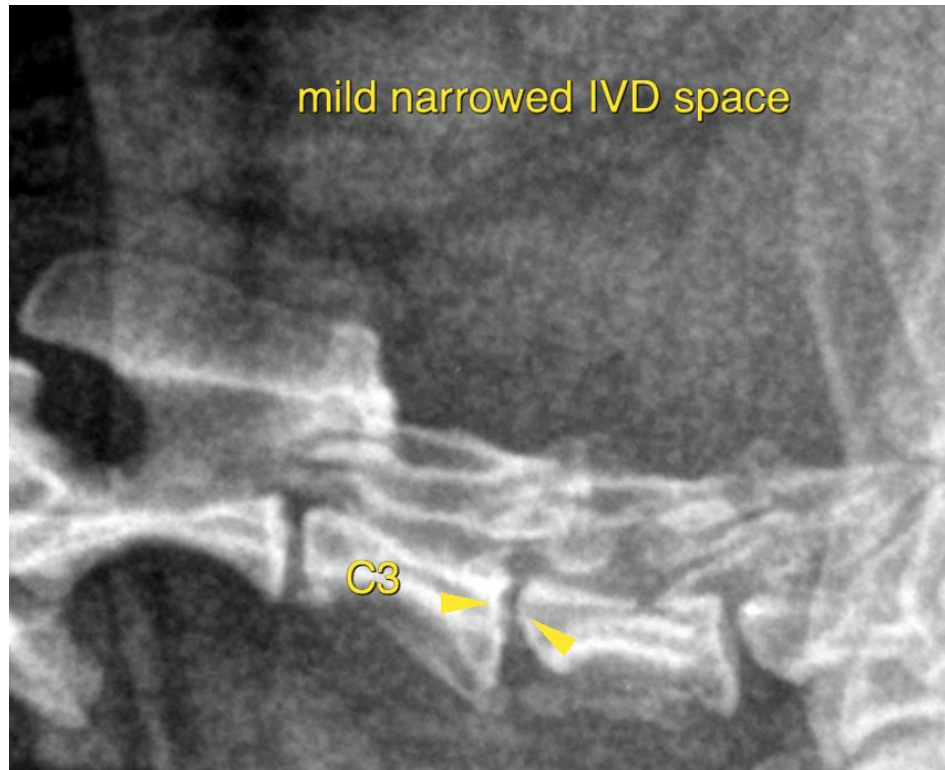
SF

AGE

11 Years, 3 Months

INTERPRETED BY

Sebastian Schaub, DVM
Dr. med. vet. DipECVDI



HOSPITAL NAME

DPC Veterinary
Hospital

REFERRING VET

Dr. White

INVOICE

55920

DATE

1-2-23

The information and recommendations provided are based on the images presented by the referring veterinarian/sonographer. No evaluation can be communicated regarding pathology that was not visible in the image/video clips provided.

Thank you for this referral. If the clinical or image interpretation does not parallel your findings or if I can be of any further assistance please contact me.

Sebastian Schaub, Sebastian Schaub, DVM, Dr. med. vet. DipECVDI
sebast.schaub@gmail.com