



## PATIENT

Nollie Gordon

## SPECIES

Canine

## BREED

Cairn Terrier

## SEX

Neutered Male

## AGE

7Y

## WEIGHT

21

## INTERPRETED BY

Sebastian Schaub, DVM  
Dr. med. vet.  
DipECVDI

## IMAGING PERFORMED BY

Robert

## HOSPITAL NAME

Aloha Pet & Bird  
Hospital

## REFERRING VET

Dr. Thompson

## INVOICE

73365

## DATE

1-19-26

## PRESENTING CLINICAL SIGNS

History:

- Gingival mass on top jaw on, recently noticed.

## COMPUTED TOMOGRAPHY OF THE SKULL

A high resolution pre- and post-contrast CT study of the skull is provided for review.

## COMPUTED TOMOGRAPHIC FINDINGS

The tooth elements 101, 102, 105, 107, 108, 201, 202, 206-208, 301-307 and 405-407 are absent. Multiple teeth present variable degree of dental resorptive lesions.

In the caudal aspect of the hard palate, a well-defined defect is appreciated in the horizontal plate of the palatine bone bilaterally – completely covered by gingiva.

Centered on the incisor bone and rostral segment of the right maxillary bone, an ill-defined, uniform soft tissue attenuating and mild irregular contrast enhancing soft tissue swelling is appreciated. The underlying incisor bone and rostral segment of the right maxillary bone – up to the level of triadan 104 – present permeative osteolysis.

The nasal cavity presents the expected aerated spaces between thin & even conchae and turbinates with smooth mucosal lining.

Both temporomandibular joints present congruent joint spaces with even subchondral bone surfaces and are considered within normal limits.

Both tympanic bullae are aerated, the mucosal lining is not seen, the bony wall is smooth and thin. The external ear canals are within normal limits.

The brain presents no deviation from normal anatomy and symmetry. The brain parenchyma is homogeneous and within normal limits for attenuation and distribution of contrast enhancement. The ventricular system is non-dilated and symmetric.

The right mandibular lymph nodes are prominent.

## COMPUTED TOMOGRAPHIC DIAGNOSIS

- Soft tissue mass centered on incisor bone & rostral segment right maxillary bone with aggressive osteolytic lesions of the underlying bone
- Mild lymphadenopathy mandibular lymph nodes
- Dental resorptive lesions multiple teeth
- Multiple absent teeth, see above
- Osseous defect hard palate – complete covered by gingiva

## INTERPRETATION OF THE FINDINGS & FURTHER RECOMMENDATIONS

The clinically appreciated gingival soft tissue mass presents a local aggressive biological behavior and primary soft tissue neoplasia is the diagnosis – differentials include fibrosarcoma, squamous cell carcinoma, melanoma, other. Theoretically osteomyelitis and inflammatory gingival hyperplasia is a differentia, but I consider the odds low. Biopsy of the gingival mass can be performed for specification. Complete surgical resection of the mass via rostral maxillectomy appears feasible. Potential osteotomy lines are distal to triadan 203 and distal to triadan 104.β'



## PATIENT

Nollie Gordon

## SPECIES

Canine

## BREED

Cairn Terrier

## SEX

Neutered Male

## AGE

7Y

## WEIGHT

21

## INTERPRETED BY

Sebastian Schaub, DVM  
Dr. med. vet.  
DipECVDI

## IMAGING PERFORMED BY

Robert

## HOSPITAL NAME

Aloha Pet & Bird  
Hospital

## REFERRING VET

Dr. Thompson

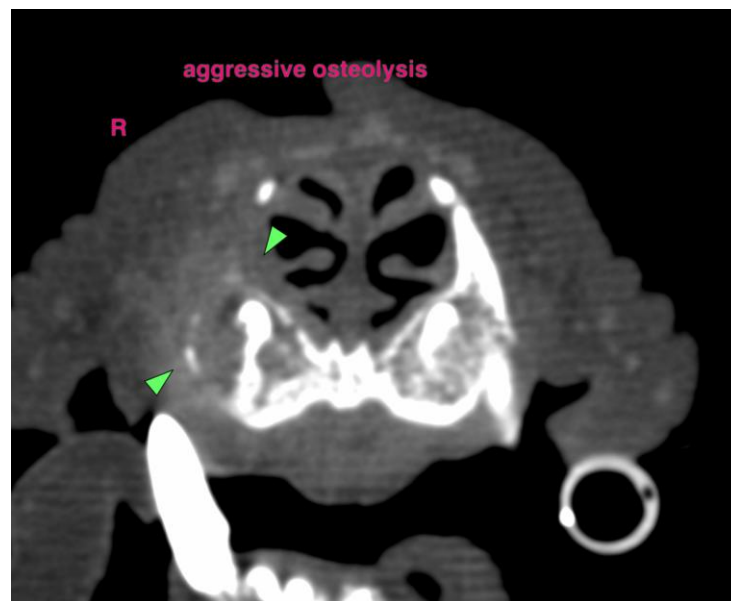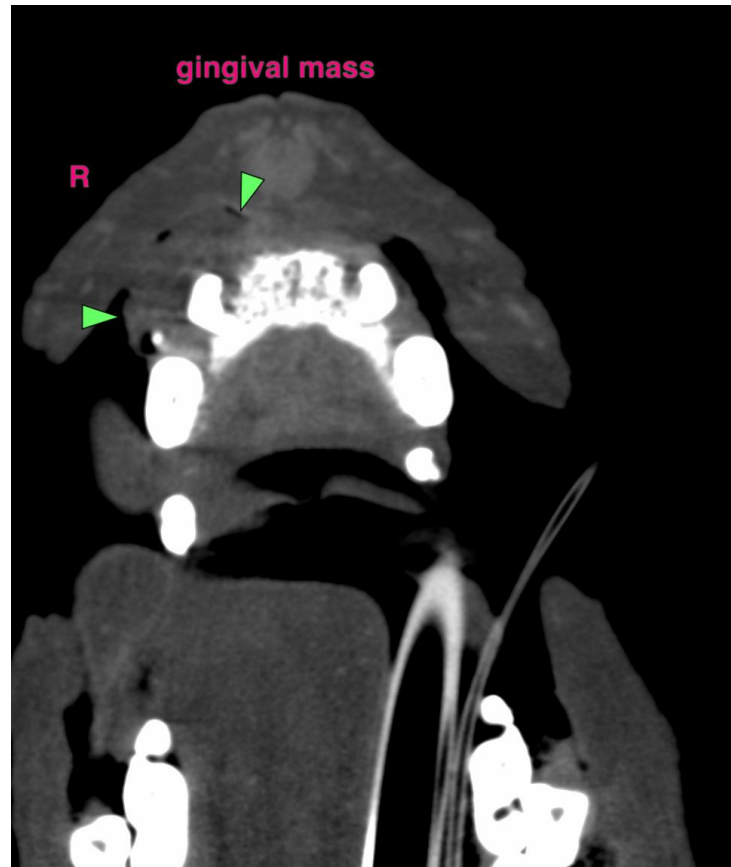
## INVOICE

73365

## DATE

1-19-26

Consider FNA sampling of the right mandibular lymph nodes to differentiate between reactive lymphoid hyperplasia versus metastatic spread.





## PATIENT

Nollie Gordon

## SPECIES

Canine

## BREED

Cairn Terrier

## SEX

Neutered Male

## AGE

7Y

## WEIGHT

21

## INTERPRETED BY

Sebastian Schaub, DVM  
Dr. med. vet.  
DipECVDI

## IMAGING PERFORMED BY

Robert

## HOSPITAL NAME

Aloha Pet & Bird  
Hospital

## REFERRING VET

Dr. Thompson

## INVOICE

73365

## DATE

1-19-26

The information and recommendations provided are based on the images presented by the referring veterinarian/sonographer. No evaluation can be communicated regarding pathology that was not visible in the image/video clips provided.

Thank you for this referral. If the clinical or image interpretation does not parallel your findings or if I can be of any further assistance please contact me.

**Sebastian Schaub**, Sebastian Schaub, DVM, Dr. med. vet. DipECVDI  
[info@sonopath.com](mailto:info@sonopath.com)