



PATIENT

Delilah Bennett

SPECIES

Canine

BREED

Mini Aussie

SEX

FS

AGE

8Y

WEIGHT

19.6lbs

INTERPRETED BY

Sebastian Schaub, DVM
Dr. med. vet.
DipECVDI

IMAGING PERFORMED BY

Grove Veterinary Clinic

HOSPITAL NAME

Grove Veterinary Clinic

REFERRING VET

Dr. Claire Lohn

INVOICE

73386

DATE

1-19-26

PRESENTING CLINICAL SIGNS

History:

- 2 month hx RF lameness

RADIOGRAPHIC STUDY OF THE ELBOW JOINTS AND CARPI

Radiographs of the right distal front limb in a mediolateral and craniocaudal view are provided for review.

RADIOGRAPHIC FINDINGS

The periarticular bones of the right elbow joint present advanced osteophyte new bone formation. The cranial tip of the medial coronoid process is ill-defined and at the base of the medial coronoid process moderate sclerosis is appreciated.

The caudal cortex of the proximal diaphysis of the right radius presents a zone with small moth eaten but well defined defects – that are also appreciated at the diaphysis of the left radius at the same level.

The osseous and surrounding soft tissue structures of the carpi reveal no abnormalities.

RADIOGRAPHIC DIAGNOSIS

- Coronoid disease right elbow joint
- Osteoarthritis right elbow joint
- Insertional desmopathy antebrachial interosseous ligament
- Normal carpal joints

INTERPRETATION OF THE FINDINGS & FURTHER RECOMMENDATIONS

The main finding is the right sided elbow dysplasia with secondary degenerative joint disease – a potential cause for the right front limb lameness. The appreciated irregularity along the caudal cortex of the radius bilaterally, is caused by osseous remodeling in the region of the insertion of the interosseous ligament and commonly an incidental finding.



PATIENT

Delilah Bennett

SPECIES

Canine

BREED

Mini Aussie

SEX

FS

AGE

8Y

WEIGHT

19.6lbs

INTERPRETED BY

Sebastian Schaub, DVM
Dr. med. vet.
DipECVDI

IMAGING PERFORMED BY

Grove Veterinary Clinic

HOSPITAL NAME

Grove Veterinary Clinic

REFERRING VET

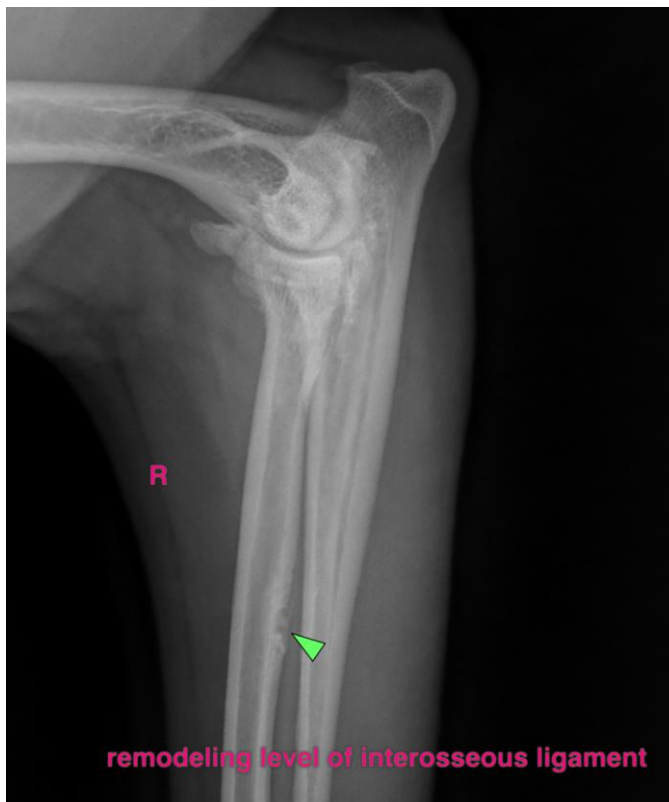
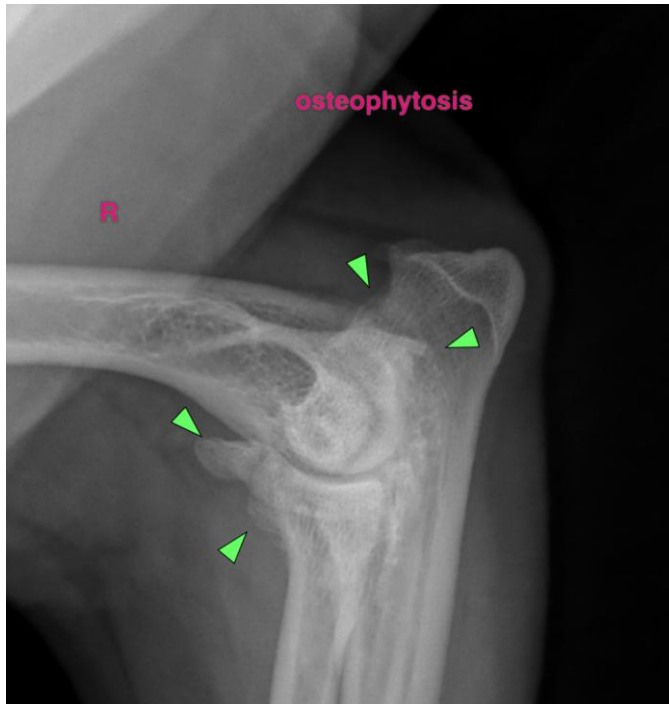
Dr. Claire Lohn

INVOICE

73386

DATE

1-19-26





PATIENT

Delilah Bennett

SPECIES

Canine

BREED

Mini Aussie

SEX

FS

AGE

8Y

WEIGHT

19.6lbs

INTERPRETED BY

Sebastian Schaub, DVM
Dr. med. vet.
DipECVDI

IMAGING PERFORMED BY

Grove Veterinary Clinic

HOSPITAL NAME

Grove Veterinary Clinic

REFERRING VET

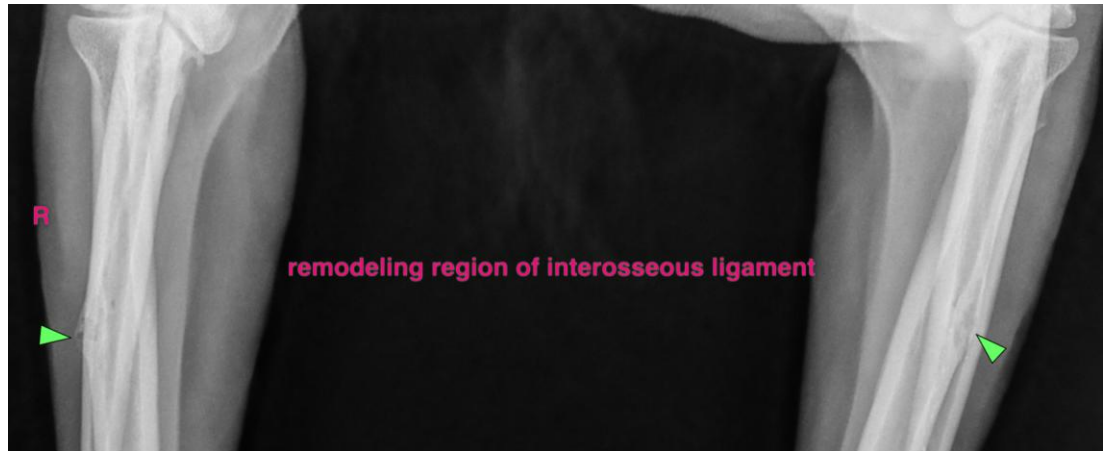
Dr. Claire Lohn

INVOICE

73386

DATE

1-19-26



The information and recommendations provided are based on the images presented by the referring veterinarian/sonographer. No evaluation can be communicated regarding pathology that was not visible in the image/video clips provided.

Thank you for this referral. If the clinical or image interpretation does not parallel your findings or if I can be of any further assistance please contact me.

Sebastian Schaub, Sebastian Schaub, DVM, Dr. med. vet. DipECVDI
info@sonopath.com