



PATIENT

Thomas Quintella

PRESENTING CLINICAL SIGNS

history of vomiting twice, diarrhea twice. History of eating foam yesterday and vomit some yesterday. Need to rule out gastroenteritis vs. obstruction

SPECIES

Feline

RADIOGRAPHIC STUDY OF THE ABDOMEN

Radiographs of the abdomen in three imaging planes are provided for review.

BREED

Russian Blue

RADIOGRAPHIC FINDINGS

The surrounding bony structures are within normal limits, the growth plates are age related open.

No abnormalities of the extraabdominal soft tissues are noted. The abdominal wall is smooth and thin.

SEX

Neutered Male

The serosal detail is maintained throughout the peritoneal and retroperitoneal space.

The liver is appropriate in position, size and presents uniform opacity.

The splenic head is in the anticipated position and within normal limits for size and opacity.

AGE

10 Months

Both kidneys are seen and present with normal size, shape, delineation and opacity. The urinary bladder is in its anticipated position. No radiopaque calculi are noted throughout the upper and lower urinary tract.

The stomach is in its anticipated position and empty.

INTERPRETED BY

Sebastian Schaub, DVM
Dr. med. vet. DipECVDI

There are multiple small intestinal segments of small intestinal loops that are mild to moderately dilated by gas. In the left abdomen a rigid appearing small intestinal loop is seen, moderately distended by fluid and foamy material.

The colon is seen in the expected position and empty but a small amount of fecal material in the ascending and transverse colon.

HOSPITAL NAME

Truscott Animal
Hospital

RADIOGRAPHIC DIAGNOSIS

- Moderate gas and fluid distension of the small intestinal loops and segmental mild foamy material in the jejunum.

REFERRING VET

Dr. Medhat Meawad

INTERPRETATION OF THE FINDINGS & FURTHER RECOMMENDATIONS

The pattern of the small intestinal loops is unfortunately not specific and equivocal for functional ileus due to enteritis/gastroenteritis or segmental mechanical obstruction. If clinical signs are refractory to therapy, recommend follow up radiographs or a complete abdominal ultrasound examination.

INVOICE

56264

DATE

1-19-23



PATIENT

Thomas Quintella

SPECIES

Feline

BREED

Russian Blue

SEX

Neutered Male

AGE

10 Months

INTERPRETED BY

Sebastian Schaub, DVM
Dr. med. vet. DipECVDI

HOSPITAL NAME

Truscott Animal
Hospital

REFERRING VET

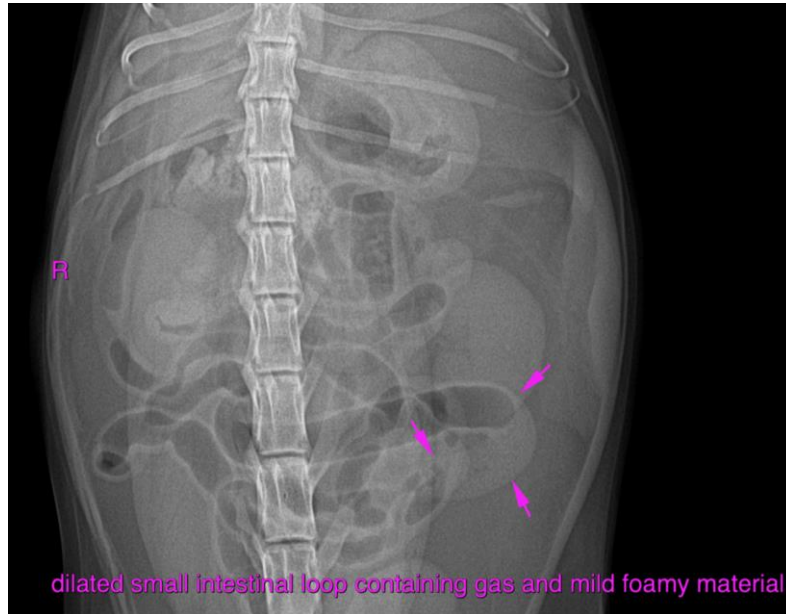
Dr. Medhat Meawad

INVOICE

56264

DATE

1-19-23



The information and recommendations provided are based on the images presented by the referring veterinarian/sonographer. No evaluation can be communicated regarding pathology that was not visible in the image/video clips provided.

Thank you for this referral. If the clinical or image interpretation does not parallel your findings or if I can be of any further assistance please contact me.

Sebastian Schaub, Sebastian Schaub, DVM, Dr. med. vet. DipECVDI
sebast.schaub@gmail.com