



**PATIENT**

Teala Elliot

**PRESENTING CLINICAL SIGNS**

Patient presents for a consult for a CT. Owner states that she is here for a scope as well. Per Owner she was vomiting Prednisolone was prescribed but did not help with appetite or vomiting. She is not taking pred now.

**SPECIES**

Feline

**COMPUTED TOMOGRAPHY OF THE THORAX AND ABDOMEN**

A high resolution pre- and post-contrast CT study of the thorax and abdomen are provided for review.

**BREED**

Ragdoll

**COMPUTED TOMOGRAPHIC FINDINGS**

Thorax

The bony and surrounding soft tissue structures are within normal limits.

**SEX**

Spayed Female

The sternal, cranial mediastinal and tracheobronchial lymph nodes are small elongated with a normal short-to-long-axis-ratio is < 0.5, the attenuation and contrast enhancement pattern is uniform and considered within normal limits.

**AGE**

14

The cardiovascular structures including the pulmonary vasculature are within normal limits.

Generalized mild to moderate peribronchial cuffing is present.

**INTERPRETED BY**

Sebastian Schaub, DVM  
Dr. med. vet. DipECVDI

The lung parenchyma presents the expected architecture and attenuation behavior.

Small incidental gas pockets are seen within the esophageal lumen, there is no evidence of abnormal dilation.

**HOSPITAL NAME**

Critical Vet  
Care/Suncoast  
Veterinary

Abdomen

The serosal fat presents normal attenuation behavior. There is no evidence of peritoneal effusion or peritonitis.

Both kidneys present within normal limits for size, shape and organ architecture. A moderate amount of mineralized material is visible in the renal pelvis bilaterally. After contrast administration a bilaterally symmetric and uniform nephro- and pyelogram is noted.

**REFERRING VET**

Dr. Young

The adrenal glands are within normal limits for size, shape and organ architecture.

**INVOICE**

49701

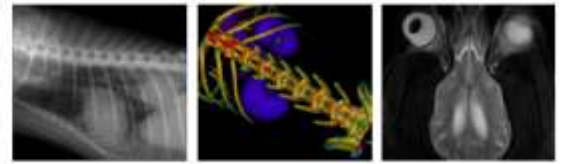
Both liver and spleen present with normal shape, even surface, uniformly attenuating parenchyma and homogeneous contrast enhancement, unremarkable.

The pancreas is evenly contoured, the pancreatic parenchyma is homogeneous and presents uniform contrast enhancement. The pancreatic duct is mildly dilated, measuring up to 1.5 mm in height.

**DATE**

1-19-22

The gastric wall of the pyloric antrum and pylorus is prominent, measuring 3.4 mm in diameter, the wall layering is maintained.



**PATIENT** Multifocal mild spondylosis formation is seen along the lumbar spine.

Teala Elliot

**COMPUTED TOMOGRAPHIC DIAGNOSIS**

**SPECIES**

Feline

- Mild mural thickening gastric wall level with pyloric antrum
- Moderate bronchial lung pattern
- Spondylosis deformans lumbar spine
- Mild dilation of the pancreatic duct – considered as an age related finding

**INTERPRETATION OF THE FINDINGS & FURTHER RECOMMENDATIONS**

**BREED**

Ragdoll

The prominent wall of the pyloric antrum is equivocal for normal anatomical variant or inflammatory changes (e.g. eosinophilic) or neoplastic disease (would expect loss of wall layering). Either gastroscopy including biopsy, ultrasound guided FNA sampling or surgical full thickness biopsy of the gastric wall might be used as advanced diagnostic test.

**SEX**

Spayed Female

The bronchial lung pattern is suggestive for (sub)clinical feline bronchial disease, due to the lack of clinical signs the clinical relevance is unclear.

**AGE**

14

**INTERPRETED BY**

Sebastian Schaub, DVM  
Dr. med. vet. DipECVDI

**HOSPITAL NAME**

Critical Vet  
Care/Suncoast  
Veterinary

**REFERRING VET**

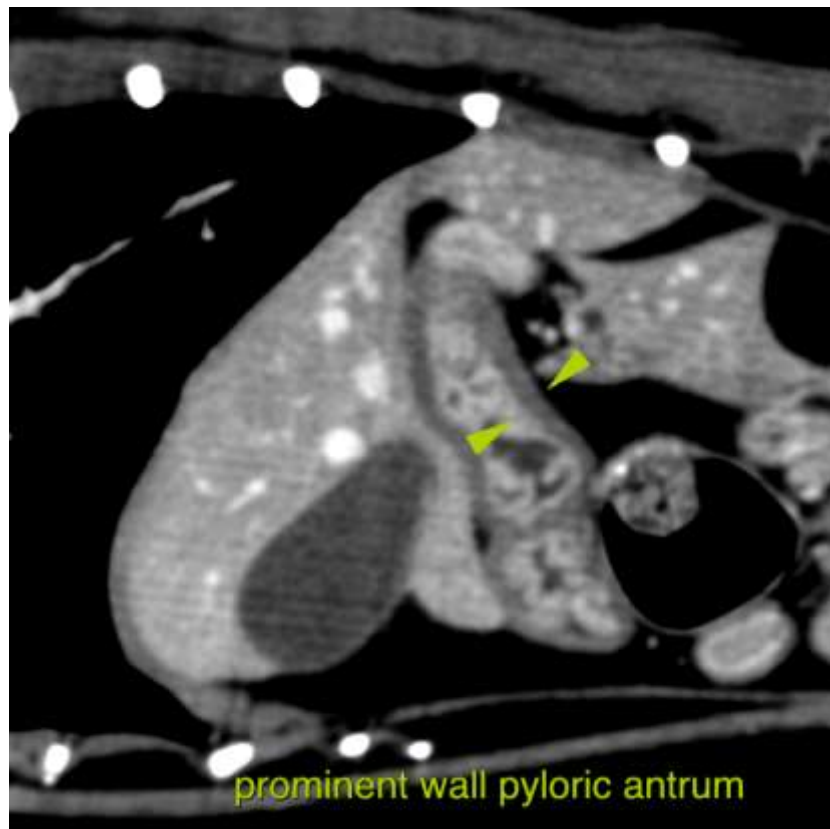
Dr. Young

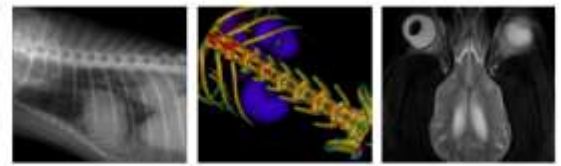
**INVOICE**

49701

**DATE**

1-19-22





**PATIENT**

Teala Elliot

**SPECIES**

Feline

**BREED**

Ragdoll

**SEX**

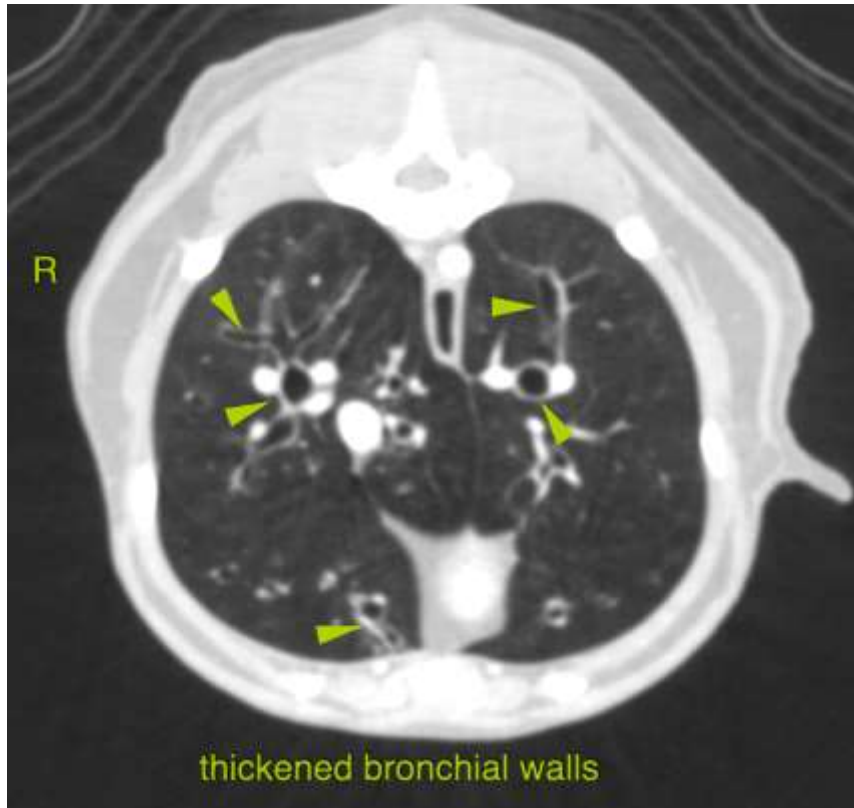
Spayed Female

**AGE**

14

**INTERPRETED BY**

Sebastian Schaub, DVM  
Dr. med. vet. DipECVDI



**HOSPITAL NAME**

Critical Vet  
Care/Suncoast  
Veterinary

**REFERRING VET**

Dr. Young

**INVOICE**

49701

**DATE**

1-19-22

The information and recommendations provided are based on the images presented by the referring veterinarian. No evaluation can be communicated regarding pathology that was not visible in the image/video clips provided.

Thank you for this referral. If the clinical or image interpretation does not parallel your findings or if I can be of any further assistance please contact me.

**Sebastian Schaub**, Sebastian Schaub, DVM, Dr. med. vet. DipECVDI  
sebast.schaub@gmail.com