



**PATIENT**

Samson Gottlieb

**PRESENTING CLINICAL SIGNS**

Oral Fibro sarcoma dx on 1/11/2022. possible surgical removal vs. oncology consult.

**COMPUTED TOMOGRAPHY OF THE SKULL**

A high resolution pre- and post-contrast CT study of the skull is provided for review.

**SPECIES**

Canine

**COMPUTED TOMOGRAPHIC FINDINGS**

The alveolar process of the left maxillary bone, level with triadan 209&210 presents permeative osteolytic lesions and a plaque like gingival mass is seen at the same level extending medially and rostrally along the horizontal plate of the left palatine bone up to the level of triadan 208; the plaque like mass is measuring approximately 2.5 x 1.7 x 4.0 cm in size. In the caudal aspect the mass is extending up to the ventral aspect of the pterygoid muscle.

**BREED**

Blue Tick Coon Hound

The medial wall of the right orbit presents focal osteolytic lesion with an associated focal soft tissue swelling, perforating the orbit and the cranial fossa at the same level.

**SEX**

MN

The nasal cavity presents the expected aerated spaces between thin & even conchae and turbinates with smooth mucosal lining.

**AGE**

10 Years

Both temporomandibular joints present congruent joint spaces with even subchondral bone surfaces and are considered within normal limits.

**INTERPRETED BY**

Sebastian Schaub, DVM  
Dr. med. vet. DipECVDI

Both tympanic bullae are aerated, the mucosal lining is not seen, the bony wall is smooth and thin. The external ear canals are within normal limits.

The brain presents no deviation from normal anatomy and symmetry. The brain parenchyma is homogeneous and within normal limits for attenuation and distribution of contrast enhancement. The ventricular system is non-dilated and symmetric.

**HOSPITAL NAME**

Stone Cottage  
Veterinary Hospital

The submandibular and medial retropharyngeal lymph nodes are small and elongated with a normal short-to-long-axis-ratio is < 0.5, the attenuation and contrast enhancement pattern is uniform.

**COMPUTED TOMOGRAPHIC DIAGNOSIS**

**REFERRING VET**

Spaccarelli

- Plaque like gingival mass level with left alveolar process of the maxillary bone
- Polyostotic aggressive osteolytic lesions left maxillary bone and medial wall of the right orbit with perforation of the cranial fossa

**INTERPRETATION OF THE FINDINGS & FURTHER RECOMMENDATIONS**

**INVOICE**

49678

The oral gingival mass is fitting the history of fibrosarcoma, invading the alveolar process of the left maxillary bone level with triadan 209&210. In the medial aspect the gingival mass is extending up to the midline and presents ill-defined margins. There is evidence of local metastasis to the medial wall of the right orbit, perforating the cranial fossa. Complete surgical resection of the oral mass would warrant extensive surgery and as the margins cannot be clearly defined, the odds for recurrence are high. Discussing the chances of palliative radiation therapy should be discussed with oncologist.

**DATE**

1-19-22

Consider full tumor staging.



**PATIENT**

Samson Gottlieb

**SPECIES**

Canine

**BREED**

Blue Tick Coon Hound

**SEX**

MN

**AGE**

10 Years

**INTERPRETED BY**

Sebastian Schaub, DVM  
Dr. med. vet. DipECVDI

**HOSPITAL NAME**

Stone Cottage  
Veterinary Hospital

**REFERRING VET**

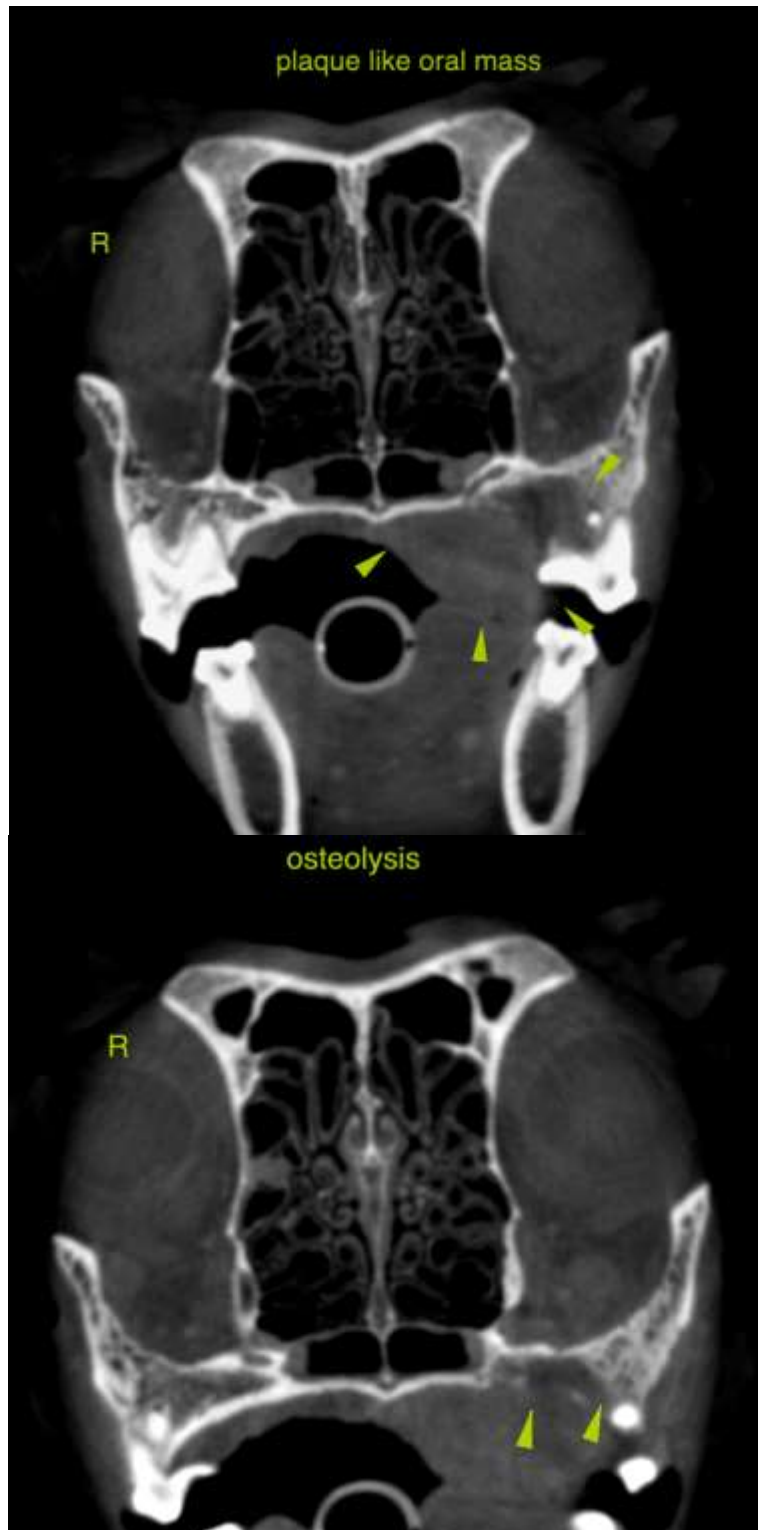
Spaccarelli

**INVOICE**

49678

**DATE**

1-19-22





**PATIENT**

Samson Gottlieb

**SPECIES**

Canine

**BREED**

Blue Tick Coon Hound

**SEX**

MN

**AGE**

10 Years

**INTERPRETED BY**

Sebastian Schaub, DVM  
Dr. med. vet. DipECVDI

**HOSPITAL NAME**

Stone Cottage  
Veterinary Hospital

**REFERRING VET**

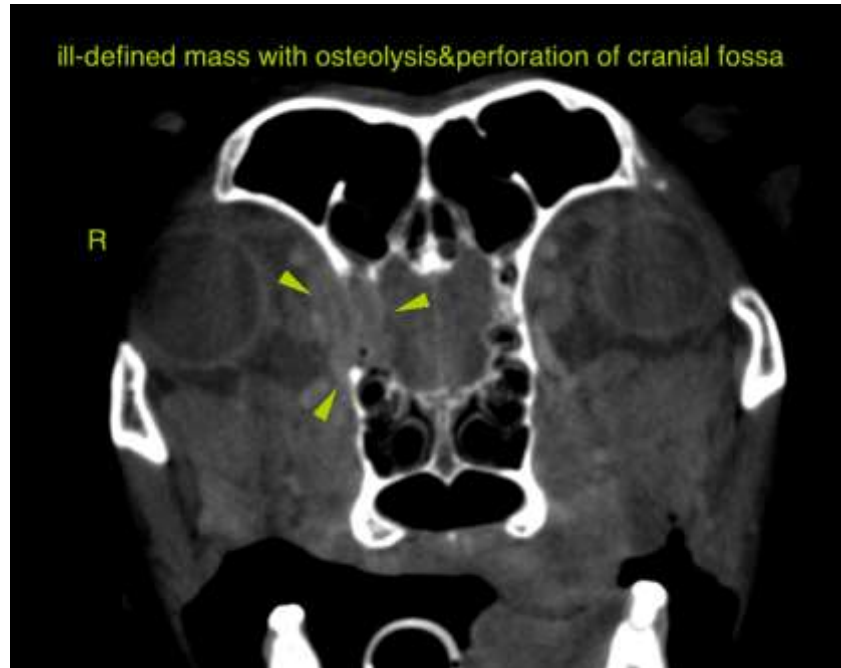
Spaccarelli

**INVOICE**

49678

**DATE**

1-19-22



The information and recommendations provided are based on the images presented by the referring veterinarian. No evaluation can be communicated regarding pathology that was not visible in the image/video clips provided.

Thank you for this referral. If the clinical or image interpretation does not parallel your findings or if I can be of any further assistance please contact me.

**Sebastian Schaub**, Sebastian Schaub, DVM, Dr. med. vet. DipECVDI  
sebast.schaub@gmail.com