



PATIENT

Lily Xu

PRESENTING CLINICAL SIGNS

Lily presented for mass removal on right side of pelvic limb. The mass has been present for some time but has recently become ulcerated. She maintains good appetite and energy level
Abnormal PE/Chem/CBC/UA Results: WBC high glucose high

SPECIES

Feline

COMPUTED TOMOGRAPHY OF THE THORAX AND ABDOMEN

A high resolution plain CT study of the thorax and abdomen is provided for review.

BREED

DSH

COMPUTED TOMOGRAPHIC FINDINGS

Generalized mild to moderate motion artefacts are present.

SEX

Female

Thorax

The bony and surrounding soft tissue structures are within normal limits.

The sternal and cranial mediastinal lymph nodes are small elongated with a normal short-to-long-axis-ratio is < 0.5, the attenuation pattern is uniform and considered within normal limits.

AGE

10 Years

The lung parenchyma is hypoinflated and the caudal lung field presents a generalized moderate ground glass attenuating parenchyma.

INTERPRETED BY

Sebastian Schaub, DVM
Dr. med. vet. DipECVDI

Small incidental gas pockets are seen within the esophageal lumen, there is no evidence of abnormal dilation.

Abdomen

The serosal fat presents normal attenuation behavior. There is no evidence of peritoneal effusion or peritonitis.

HOSPITAL NAME

Animal Surgical Cener

Both kidneys present within normal limits for size, shape and organ architecture. A mild amount of mineralized material is seen in the left renal pelvis.

REFERRING VET

Dr. Short

The adrenal glands are within normal limits for size, shape and organ architecture.

Both liver and spleen present with normal shape, even surface, uniformly attenuating parenchyma.

INVOICE

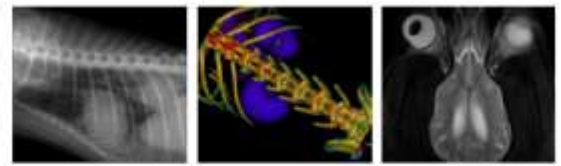
49703

The position, delineation, wall and content of the gastrointestinal tract are considered within normal limits throughout.

DATE

1-19-22

At the lateral aspect of the right thigh, a large, soft tissue attenuating mass, measuring at least 10.3 x 6.0 x 11.6 cm in size; the mass presents multifocal heterogeneous mineralization. In cranioproximal aspect the mass is extending up to the lateral aspect of the right iliac wing. The surrounding fat presents moderate fat-stranding. The right iliac wing and femur present no abnormalities.



PATIENT **COMPUTED TOMOGRAPHIC DIAGNOSIS**

- Lily Xu
- Large soft tissue mass right thigh & gluteal region with dystrophic mineralization
 - Unstructured interstitial lung pattern with reduced volume of the lung parenchyma
 - Nephrolithiasis without evidence of obstruction

SPECIES **INTERPRETATION OF THE FINDINGS & FURTHER RECOMMENDATIONS**

Feline

The CT study is consistent with the history of soft tissue neoplasm originating from the right thigh/extending up into the gluteal region. Sarcoma is likely here. Complete surgical resection will warrant amputation of the right hind limb and hemipelvectomy might be considered as well as the mass is extending up to the right iliac wing.

BREED

DSH

The unstructured interstitial lung pattern is most likely a sequela to hypoinflation of the lung parenchyma. However, if a 'real' interstitial pattern is present, potentials include fibrosis, pneumonitis (infectious versus primary inflammatory), systemic disease (e.g. pancreatitis, renal disease), neoplasia. In case of doubt BAL can be used as an advanced diagnostic test.

SEX

Female

AGE

10 Years

INTERPRETED BY

Sebastian Schaub, DVM
Dr. med. vet. DipECVDI

HOSPITAL NAME

Animal Surgical Cener

REFERRING VET

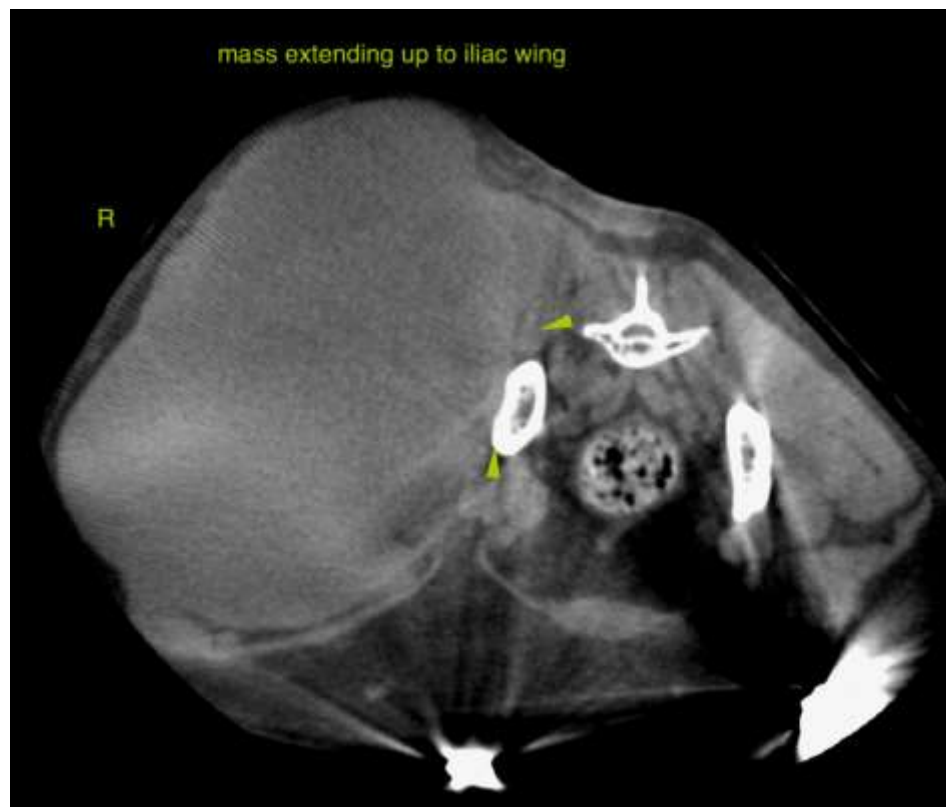
Dr. Short

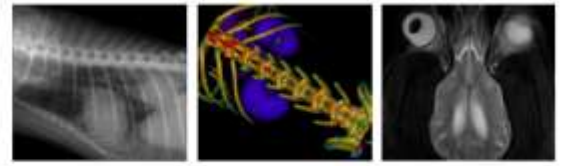
INVOICE

49703

DATE

1-19-22





PATIENT

Lily Xu

SPECIES

Feline

BREED

DSH

SEX

Female

AGE

10 Years

INTERPRETED BY

Sebastian Schaub, DVM
Dr. med. vet. DipECVDI

HOSPITAL NAME

Animal Surgical Cener

REFERRING VET

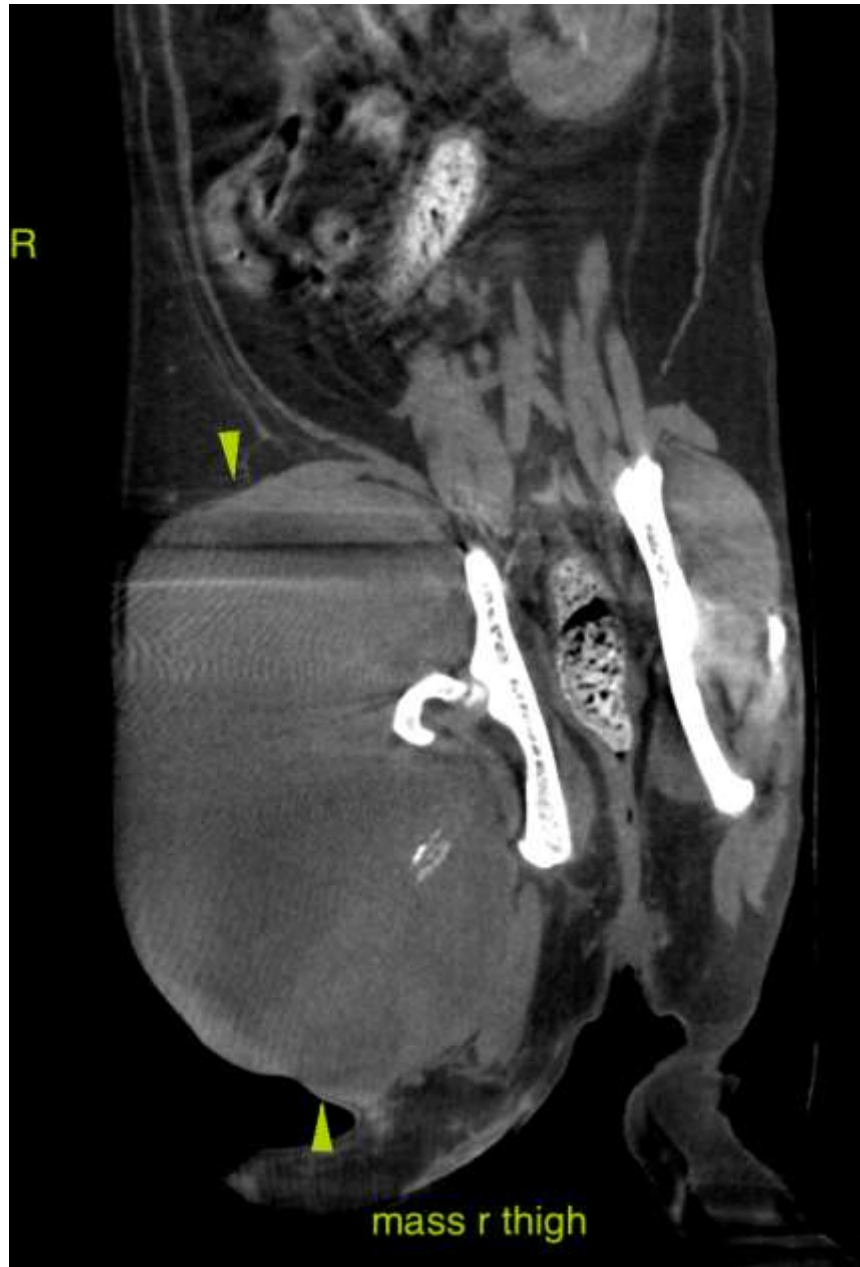Dr. Short

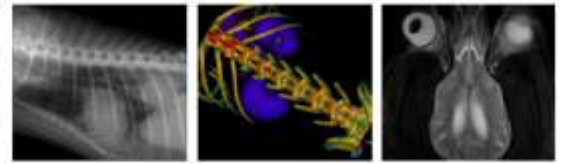
INVOICE

49703

DATE

1-19-22





PATIENT

Lily Xu

SPECIES

Feline

BREED

DSH

SEX

Female

AGE

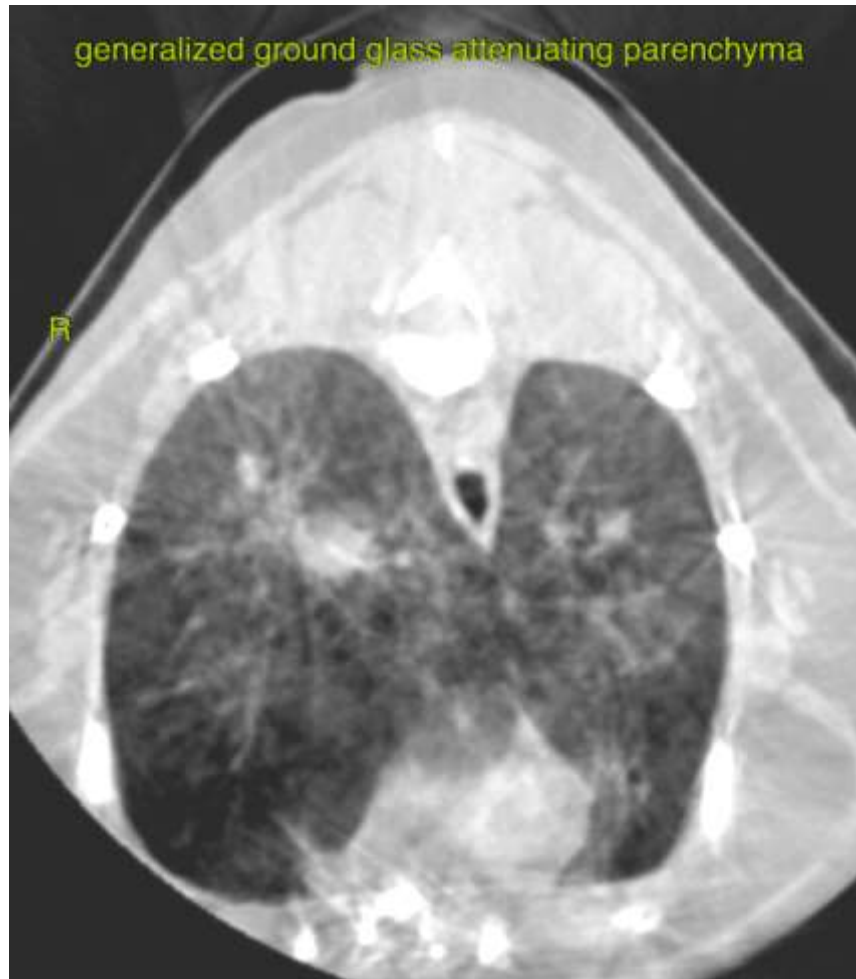
10 Years

INTERPRETED BY

Sebastian Schaub, DVM
Dr. med. vet. DipECVDI

HOSPITAL NAME

Animal Surgical Cener



REFERRING VET

Dr. Short

INVOICE

49703

DATE

1-19-22

The information and recommendations provided are based on the images presented by the referring veterinarian. No evaluation can be communicated regarding pathology that was not visible in the image/video clips provided.

Thank you for this referral. If the clinical or image interpretation does not parallel your findings or if I can be of any further assistance please contact me.

Sebastian Schaub, Sebastian Schaub, DVM, Dr. med. vet. DipECVDI
sebast.schaub@gmail.com