



PATIENT PRESENTING CLINICAL SIGNS

Neeko Marquez Seizures since Oct. 2022 that have been progressing despite being on Phenobarbital and Kepra.

COMPUTED TOMOGRAPHY OF THE SKULL

SPECIES A high resolution pre- and post-contrast CT study of the skull is provided for review.

Canine **COMPUTED TOMOGRAPHIC FINDINGS**

A fourth mandibular molar tooth is appreciated bilaterally.

BREED The nasal cavity presents the expected aerated spaces between thin & even conchae and turbinates with smooth mucosal lining.

American Bulldog Both temporomandibular joints present congruent joint spaces with even subchondral bone surfaces and are considered within normal limits.

SEX Both tympanic bullae are aerated, the mucosal lining is not seen, the bony wall is smooth and thin. The external ear canals are within normal limits.

Neutered Male

AGE Post contrast administration, in the right temporal lobe, a peripheral contrast enhancing, irregular shaped lesion is seen, measuring 14 x 13 x 23 mm in size. The volume of the right temporal lobe is increased, and the right lateral ventricle is distorted.

2 Years The submandibular and medial retropharyngeal lymph nodes are small and elongated with a normal short-to-long-axis-ratio is < 0.5, the attenuation and contrast enhancement pattern is uniform.

INTERPRETED BY COMPUTED TOMOGRAPHIC DIAGNOSIS

Sebastian Schaub, DVM
Dr. med. vet. DipECVDI

- Solitary intracranial intraaxial peripheral contrast enhancing irregular shaped lesion right temporal lobe
- Fourth mandibular molar tooth bilaterally

HOSPITAL NAME

Mobile Pet Imaging

INTERPRETATION OF THE FINDINGS & FURTHER RECOMMENDATIONS

REFERRING VET

Meaux

The intracranial lesion of the right temporal lobe is a plausible explanation for the progressive seizure activity, the lesion is concerning for primary neoplasia of the brain such as glioblastoma. A differential can be brain abscess or granuloma, but the odds are low. Complementing workup by CSF tap can be used as advanced diagnostic tool.

INVOICE

56244

DATE

1-18-23



PATIENT

Neeko Marquez

SPECIES

Canine

BREED

American Bulldog

SEX

Neutered Male

AGE

2 Years

INTERPRETED BY

Sebastian Schaub, DVM
Dr. med. vet. DipECVDI

HOSPITAL NAME

Mobile Pet Imaging

REFERRING VET

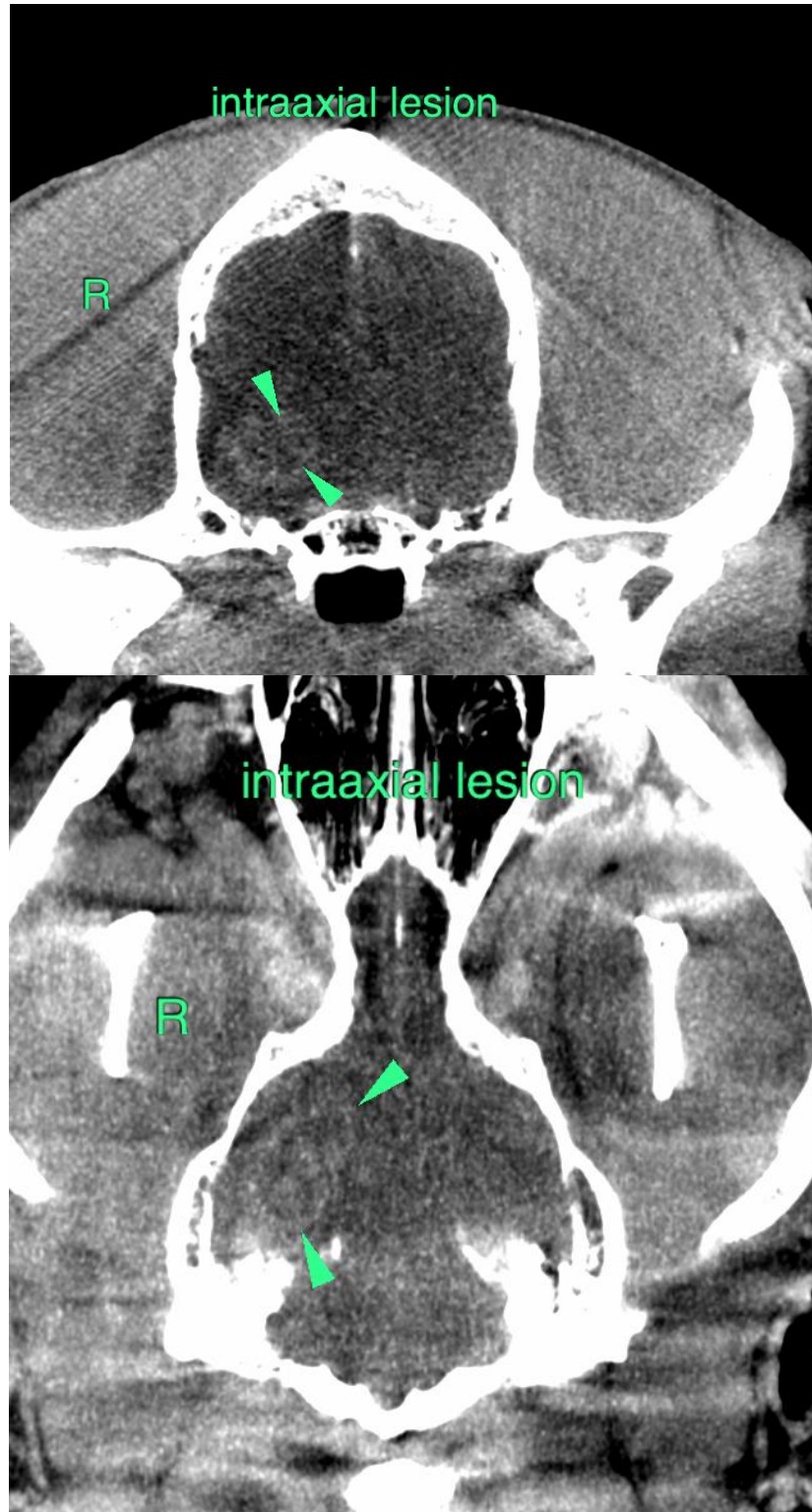
Meaux

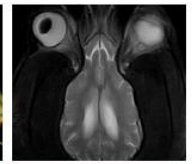
INVOICE

56244

DATE

1-18-23





PATIENT

Neeko Marquez

SPECIES

Canine

The information and recommendations provided are based on the images presented by the referring veterinarian/sonographer. No evaluation can be communicated regarding pathology that was not visible in the image/video clips provided.

BREED

American Bulldog

Thank you for this referral. If the clinical or image interpretation does not parallel your findings or if I can be of any further assistance please contact me.

Sebastian Schaub, Sebastian Schaub, DVM, Dr. med. vet. DipECVDI
sebast.schaub@gmail.com

SEX

Neutered Male

AGE

2 Years

INTERPRETED BY

Sebastian Schaub, DVM
Dr. med. vet. DipECVDI

HOSPITAL NAME

Mobile Pet Imaging

REFERRING VET

Meaux

INVOICE

56244

DATE

1-18-23