

**PATIENT PRESENTING CLINICAL SIGNS**

Meika Pegg Soft tissue sarcoma (right hip).

COMPUTED TOMOGRAPHY OF THE PELVIS

SPECIES A high resolution pre- and post-contrast CT study of the pelvis is provided for review.

Canine **COMPUTED TOMOGRAPHIC FINDINGS**

BREED Arising from the right gluteal muscle, a soft tissue attenuating ovoidal shaped mass is seen, presenting a heterogeneous mild contrast enhancement pattern. The mass is measuring 7.7 x 5.7 x 11.6 cm in size. The mass is extending from the cranial margin of the right iliac wing up to the level of the greater trochanter of the femur. The right iliac wing has smooth margins.

Siberian Husky

The right medial iliac lymph nodes is prominent and has a heterogeneous contrast enhancing.

SEX The periarticular bones of the coxofemoral joints present mild osteophyte new bone formation.

Spayed Female

COMPUTED TOMOGRAPHIC DIAGNOSIS

- Soft tissue mass right gluteus medius muscle
- Lymphadenopathy right medial iliac lymph node
- Mild degenerative osteoarthritis coxofemoral joints bilaterally

10 Years

INTERPRETATION OF THE FINDINGS & FURTHER RECOMMENDATIONS**INTERPRETED BY**

Sebastian Schaub, DVM
Dr. med. vet. DipECVDI

The soft tissue mass originating from the right gluteus medius muscle is fitting the history of sarcoma. There is no evidence of associated aggressive bone lesions, however complete surgical resection will likely warrant right sided hemipelvectomy with amputation of the right hind limb. There is an increased risk for reoccurrence due to invasion of the axial musculature at the same level.

HOSPITAL NAME

Mobile Pet Imaging

The enlarged right medial iliac lymph node is highly suggestive for metastatic spread.

Consider full tumor staging.

REFERRING VET

Meaux

INVOICE

56232

DATE

1-18-23



PATIENT

Meika Pegg

SPECIES

Canine

BREED

Siberian Husky

SEX

Spayed Female

AGE

10 Years

INTERPRETED BY

Sebastian Schaub, DVM
Dr. med. vet. DipECVDI

HOSPITAL NAME

Mobile Pet Imaging

REFERRING VET

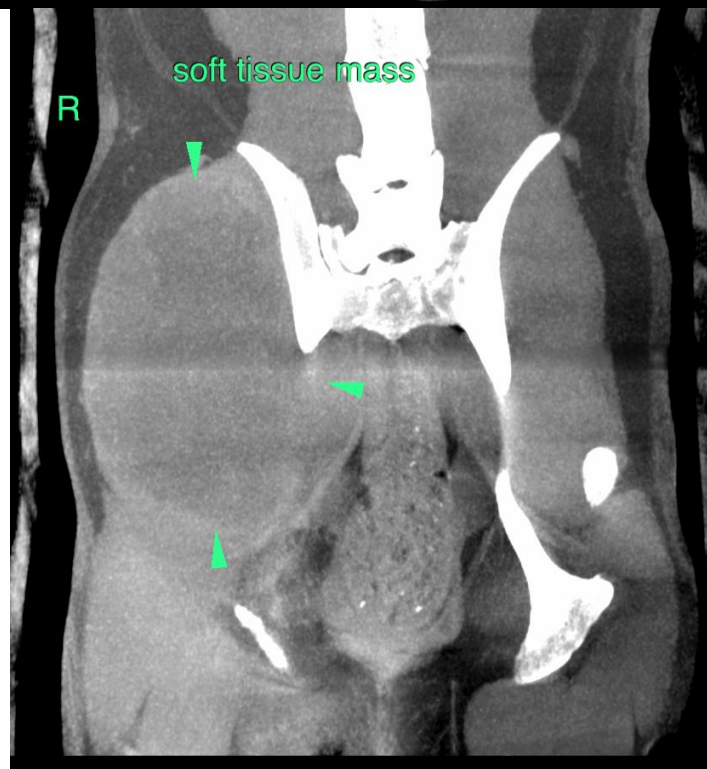
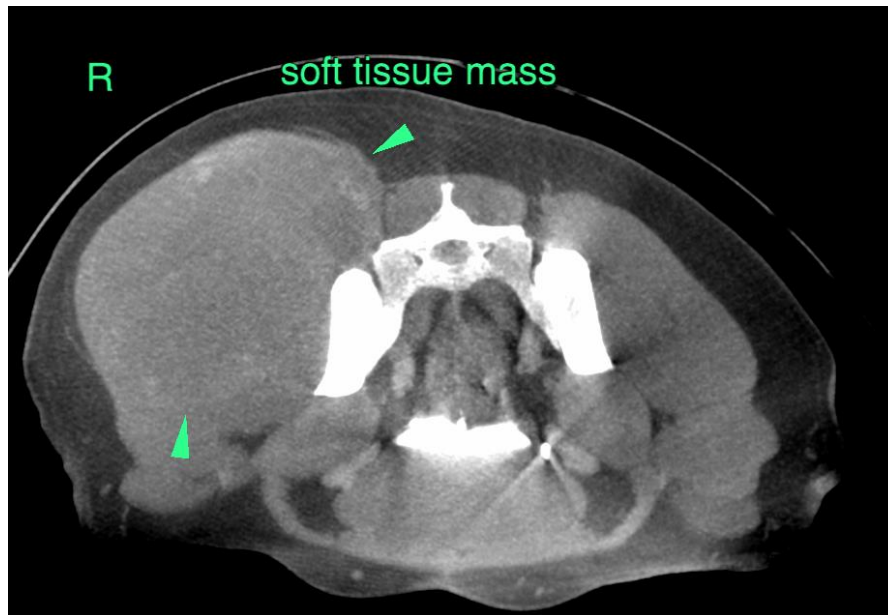Meaux

INVOICE

56232

DATE

1-18-23





PATIENT

Meika Pegg

SPECIES

Canine

BREED

Siberian Husky

SEX

Spayed Female

AGE

10 Years

INTERPRETED BY

Sebastian Schaub, DVM
Dr. med. vet. DipECVDI

HOSPITAL NAME

Mobile Pet Imaging

REFERRING VET

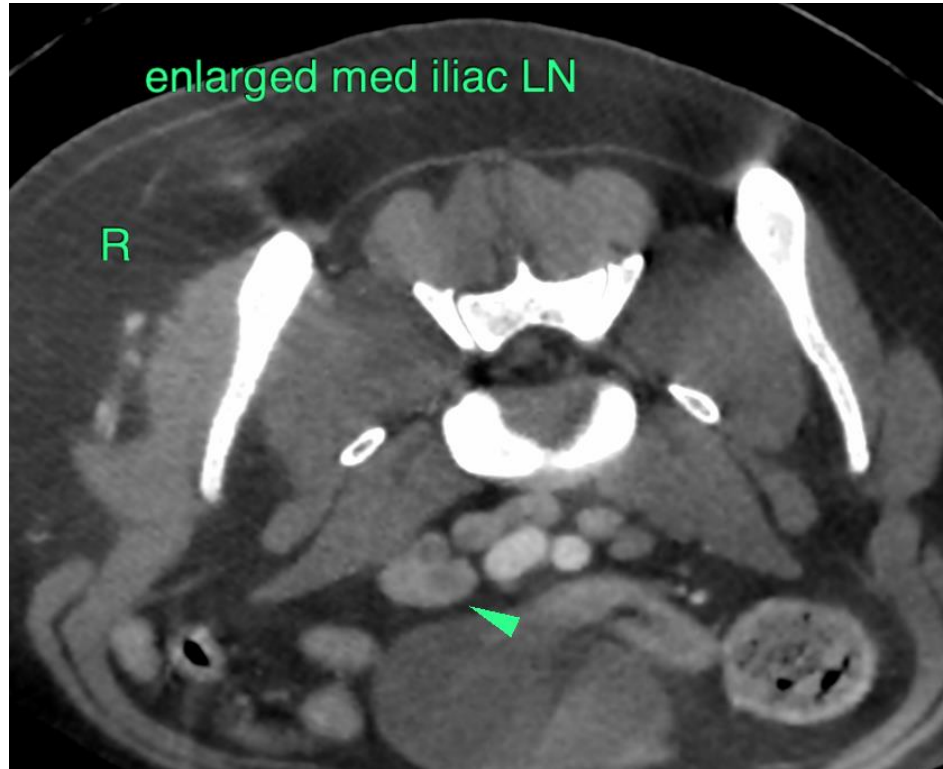
Meaux

INVOICE

56232

DATE

1-18-23



The information and recommendations provided are based on the images presented by the referring veterinarian/sonographer. No evaluation can be communicated regarding pathology that was not visible in the image/video clips provided.

Thank you for this referral. If the clinical or image interpretation does not parallel your findings or if I can be of any further assistance please contact me.

Sebastian Schaub, Sebastian Schaub, DVM, Dr. med. vet. DipECVDI
sebast.schaub@gmail.com