

**PATIENT PRESENTING CLINICAL SIGNS**

Buddy Kiernan Otitis L &gt; R, R/O polyps vs other.

**COMPUTED TOMOGRAPHY OF THE SKULL****SPECIES** A high resolution pre- and post-contrast CT study of the skull is provided for review.Feline **COMPUTED TOMOGRAPHIC FINDINGS**

The tooth elements 301 is absent. Triadan 104 &amp; 204 present mild resorptive lesions of the roots with ankylosis.

**BREED** The nasal cavity presents the expected aerated spaces between thin & even conchae and turbinates with smooth mucosal lining.  
DSH**SEX** Both temporomandibular joints present congruent joint spaces with even subchondral bone surfaces and are considered within normal limits.

Neutered Male Both tympanic bullae are aerated, the mucosal lining is not seen, the bony wall is smooth and thin. The external ear canals present a prominent, mild irregular wall, R&gt;L.

**AGE** The brain presents no deviation from normal anatomy and symmetry. The brain parenchyma is homogeneous and within normal limits for attenuation and distribution of contrast enhancement. The ventricular system is non-dilated and symmetric.

12 Years The submandibular and medial retropharyngeal lymph nodes are small and elongated with a normal short-to-long-axis-ratio is &lt; 0.5, the attenuation and contrast enhancement pattern is uniform.

**INTERPRETED BY**Sebastian Schaub, DVM  
Dr. med. vet. DipECVDI**COMPUTED TOMOGRAPHIC DIAGNOSIS**

- History of bilateral otitis externa
- Tooth root resorption and ankylosis triadan 104 and 204
- Absent triadan 301

**HOSPITAL NAME**

Mobile Pet Imaging

**INTERPRETATION OF THE FINDINGS & FURTHER RECOMMENDATIONS****REFERRING VET**

The CT study is fitting the history of bilateral otitis externa, an underlying cause such as polyp or mass is not appreciated.

Meaux

**INVOICE**

56222

**DATE**

1-18-23



**PATIENT**

Buddy Kiernan

**SPECIES**

Feline

**BREED**

DSH

**SEX**

Neutered Male

**AGE**

12 Years

**INTERPRETED BY**

Sebastian Schaub, DVM  
Dr. med. vet. DipECVDI

**HOSPITAL NAME**

Mobile Pet Imaging

**REFERRING VET**

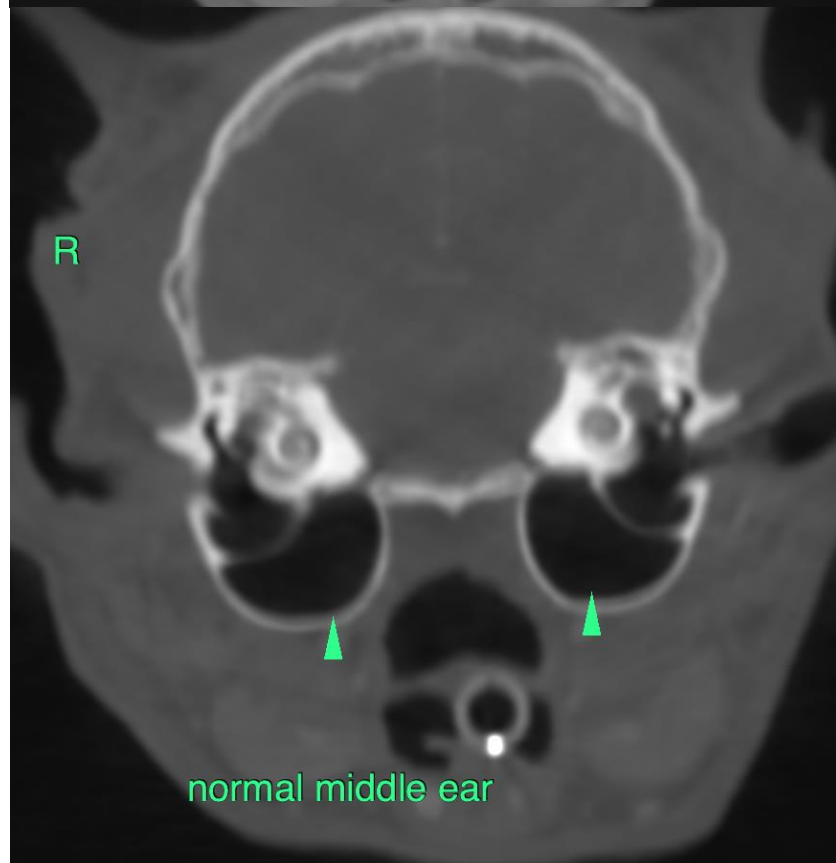
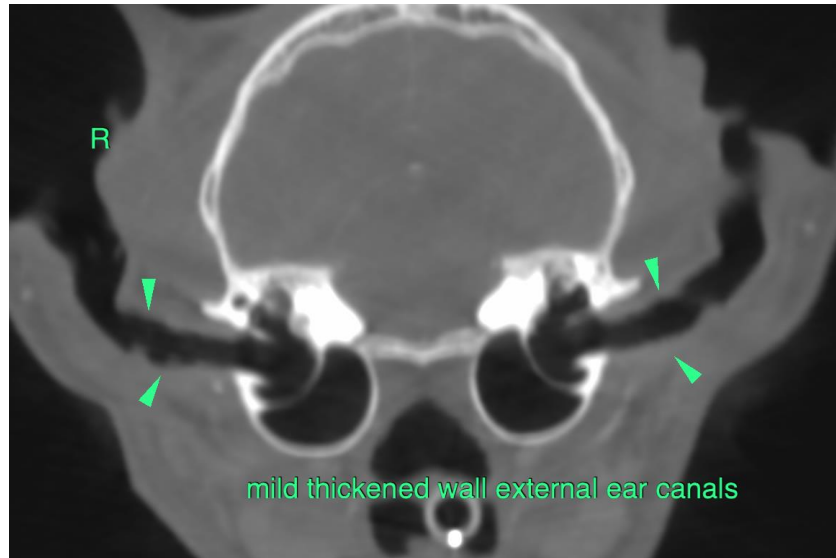
Meaux

**INVOICE**

56222

**DATE**

1-18-23





**PATIENT**

Buddy Kiernan

**SPECIES**

Feline

The information and recommendations provided are based on the images presented by the referring veterinarian/sonographer. No evaluation can be communicated regarding pathology that was not visible in the image/video clips provided.

**BREED**

DSH

Thank you for this referral. If the clinical or image interpretation does not parallel your findings or if I can be of any further assistance please contact me.

**Sebastian Schaub**, Sebastian Schaub, DVM, Dr. med. vet. DipECVDI  
sebast.schaub@gmail.com

**SEX**

Neutered Male

**AGE**

12 Years

**INTERPRETED BY**

Sebastian Schaub, DVM  
Dr. med. vet. DipECVDI

**HOSPITAL NAME**

Mobile Pet Imaging

**REFERRING VET**

Meaux

**INVOICE**

56222

**DATE**

1-18-23