



PATIENT

Phoebe Hamada

PRESENTING CLINICAL SIGNS

1/18/22 - 7 Month Post RT: Phoebe seems to be doing well. Eating and drinking well. Sometimes panting while relaxed which is not normal for her. Going for a couple walks a day - still active and playful. No vomiting or diarrhea. Was seen 11/22 after jumping out of the car and may have sprained her front carpal/metacarpal joint(s). She has been on rimadyl as needed. #9/27/21 - 3

SPECIES

Canine

Month Post RT: The left thyroid mass is reducing in size. There is thickening palpable in the left ventral neck but a well defined mass is not easily discerned. She is breathing well without any evidence of laryngeal obstruction. Contrast CT of the neck shows the mass is reduced in size compared to pre radiation therapy. Margins of the mass are contrast enhanced and the center is non contrast enhancing supportive of reduced blood supply or necrotic tissue. The endoscopy findings of the larynx show there is no recurrence of the mass within the laryngeal lumen and the mucosa has healed well. The original size of the left thyroid mass was 74 mm in length x 30 mm in width x 34 mm in height. Now the mass measures 41 mm in length x 19.7 mm in width x 19.2 mm in height. #6/24/21 - HDR Brachytherapy: The owner reports that Phoebe is doing okay. Her appetite and energy levels are good. She still has a cough. Sometimes her bark sounds different.

BREED

Mini Aussie

The thyroid carcinoma is reduced in size compared to last month. The mass measured 74 mm in length x 30 mm in width x 34 mm in height last month. The mass now measures 50.1 mm in length x 26.8 mm in height x 32 mm in width. Mass tissue within the larynx has receded and appears to be healing well. The mass deep to the left vocal fold is also reduced in size compared to last month. She appears to be responding to the initial dose of radiation therapy. A dose of 12 Gy was delivered today. #5/26/21 - HDR Brachytherapy: She was much improved after the laryngeal mass debulking procedure and was able to breathe more freely. Appetite and activity have been normal. She does cough some in the morning. She is not acting painful. The owner reports that her breathing has become labored in the last few days, her bark has changed and she has had reduced energy for the last 2 days. The mass within the lumen of the larynx has grown a small amount compared to post debulking 1 month ago. There is also mass tissue beneath the left vocal fold that appears to be larger than before. The mass beneath the vocal fold appears to cause some airway obstruction. The lumen of the larynx remains patent. A dose 12 Gy is delivered to the thyroid carcinoma. Good margins and coverage are obtained. A second dose of radiation therapy is recommended in 1 month. Carprofen and clindamycin are dispensed. Drainage from the catheter sites may persist for several days and should be wiped away with a wet cloth to keep her neck clean. #4/29/21 - CT/Bronchoscopy: Phoebe presented on 4/29/21 with a 6 month history of intermittent heavy breathing. The owner describes wheezing on inspiration. The abnormal breathing usually occurs in the morning and also occurs during exercise. Her episodic abnormal breathing is similar to a reverse sneeze but not as loud. Appetite and activity are normal. She starts heavy breathing sooner than she used to during exercise. She is not currently on any medication. Radiographs: There is a soft tissue opacity and narrowing of the lumen of the larynx. The cranial cervical trachea is deviated towards the right. An ill-defined mass effect is located in the area of the left thyroid gland. CT and bronchoscopy findings documented the presence of a large mass arising from the area of the left thyroid gland. Biopsies confirm a thyroid carcinoma. The carcinoma is invasive and has eroded through the wall of the larynx and proximal trachea, esophagus and carotid artery. There was no evidence of enlarged cervical lymph nodes or pulmonary masses or nodules. The mass within the laryngeal lumen causing airway obstruction was resected for palliation using a Coblation wand.

SEX

SF

Abnormal PE/Chem/CBC/UA Results: Bloodwork is dated 1/9/22. CBC - PCV = 51%, WBC = 6200, neutrophils = 4774, lymphocytes = 558, monocytes = 558. Platelets = 266,000. Chemistry - Cholesterol 349, all else normal. Urinalysis - USG = 1.034, pH = 8.0, trace protein, WBC = 0, RBC = 0, no bacteria. T4 = 2.2. HWT - negative. Laryngoscopy/Tracheoscopy: The larynx and distal trachea are imaged using a 2.7 mm rigid endoscope. There is no visible mass tissue extending into the lumen of the larynx or trachea. The left wall of the larynx/trachea is slightly erythematous and there are a few petehiae. There is scar tissue where mass tissue was previously removed. The

AGE

9 Years

INTERPRETED BY

Sebastian Schaub, DVM
Dr. med. vet. DipECVDI

HOSPITAL NAME

VetMed Consultants

REFERRING VET

Kanda Hazelwood

INVOICE

49665

DATE

1-18-22

**PATIENT**

Phoebe Hamada

left arytenoid cartilage is fixed in position and does not abduct during inspiration. The laryngeal/tracheal lumen is normal diameter.

COMPUTED TOMOGRAPHY OF THE NECK AND THORAX**SPECIES**

Canine

High resolution pre- and post-contrast CT studies of the neck and thorax are provided for review.

COMPUTED TOMOGRAPHIC FINDINGS**BREED**

Mini Aussie

Neck

Originating from the left thyroid gland, a soft tissue attenuating and heterogeneous significantly contrast enhancing plaque like mass is visible, measuring approximately 2.9 x 1.8 x 4.4 cm in size – decreased in size in comparison to the preceding CT study. The mass merges with the esophageal, tracheal wall at the same level and the left vocal fold is swollen with a heterogeneous contrast enhancement pattern. Overall, the size of the mass and intramural changes of the esophageal wall, trachea and vocal fold are decreased in size in comparison to the first CT study.

SEX

SF

The pictured parts of the skull are within normal limits.

AGE

9 Years

Thorax

Mild spondylosis formation is seen along the caudal thoracic spine.

INTERPRETED BY

Sebastian Schaub, DVM
Dr. med. vet. DipECVDI

The sternal, cranial mediastinal and tracheobronchial lymph nodes are small elongated with a normal short-to-long-axis-ratio is < 0.5, the attenuation and contrast enhancement pattern is uniform and considered within normal limits.

The cardiovascular structures including the pulmonary vasculature are within normal limits.

HOSPITAL NAME

VetMed Consultants

The bronchial tree presents with regular branching and tapers uniformly towards the periphery as expected, the bronchial walls are thin and smooth. The bronchus-to-artery ratio is within normal limits.

The lung parenchyma presents the expected architecture and attenuation behavior.

REFERRING VET

Kanda Hazelwood

Small incidental gas pockets are seen within the esophageal lumen, there is no evidence of abnormal dilation.

COMPUTED TOMOGRAPHIC DIAGNOSIS**INVOICE**

49665

- History of left thyroid carcinoma with local invasive growth and infiltration of the tracheal and esophageal wall
- Spondylosis deformans
- No evidence of pulmonary metastatic disease

DATE

1-18-22

INTERPRETATION OF THE FINDINGS & FURTHER RECOMMENDATIONS

Overall, the tumor size of the left thyroid is reduced in comparison to the previous CT study dated 4/30/21. There is evidence of persistent mural invasion of the esophageal & tracheal wall with regression of the size in comparison to the previous CT study.



PATIENT

There is no evidence of metastatic disease

Phoebe Hamada

SPECIES

Canine

BREED

Mini Aussie

SEX

SF

AGE

9 Years

INTERPRETED BY

Sebastian Schaub, DVM
Dr. med. vet. DipECVDI

HOSPITAL NAME

VetMed Consultants

REFERRING VET

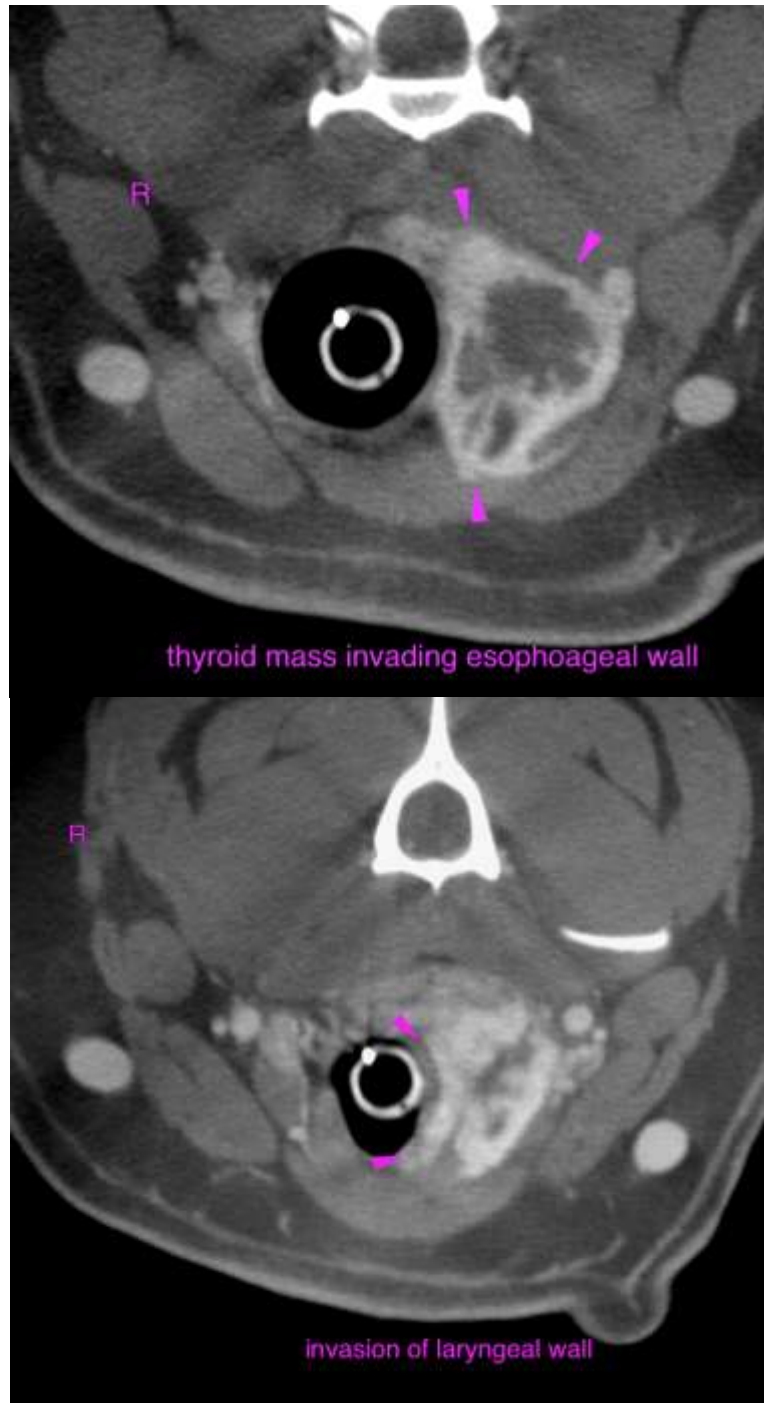
Kanda Hazelwood

INVOICE

49665

DATE

1-18-22





PATIENT

Phoebe Hamada

SPECIES

Canine

BREED

Mini Aussie

SEX

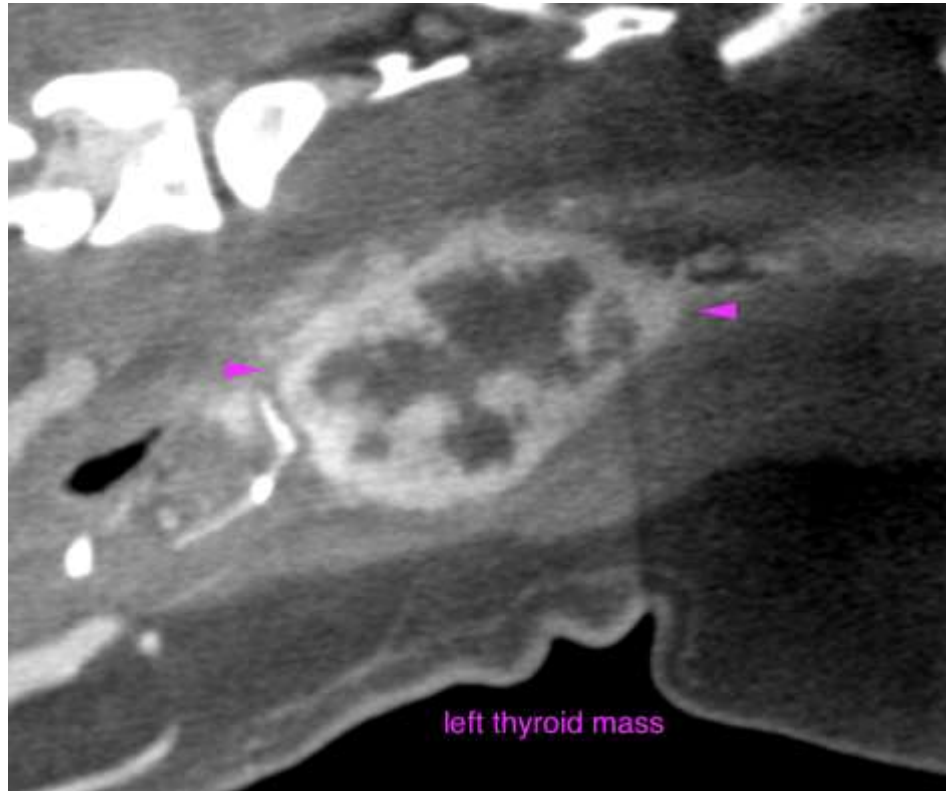
SF

AGE

9 Years

INTERPRETED BY

Sebastian Schaub, DVM
Dr. med. vet. DipECVDI



HOSPITAL NAME

VetMed Consultants

REFERRING VET

Kanda Hazelwood

INVOICE

49665

DATE

1-18-22

The information and recommendations provided are based on the images presented by the referring veterinarian. No evaluation can be communicated regarding pathology that was not visible in the image/video clips provided.

Thank you for this referral. If the clinical or image interpretation does not parallel your findings or if I can be of any further assistance please contact me.

Sebastian Schaub, Sebastian Schaub, DVM, Dr. med. vet. DipECVDI
sebast.schaub@gmail.com