



PATIENT

Teddy Moffitt

SPECIES

Feline

BREED

DSH

SEX

Male Neutered

AGE

13 Years

INTERPRETED BY

Sebastian Schaub, DVM
Dr. med. vet. DipECVDI

HOSPITAL NAME

Long Valley Animal
Hospital

REFERRING VET

Russell Early

INVOICE

49627

DATE

1-17-22

PRESENTING CLINICAL SIGNS

On 12/17/21. pet experienced a brief event upon recovery of anesthesia---started sneezing violently and had small drop of blood from right nostril. Thoracic x-rays at that time (post-anesthesia) revealed consolidation of R middle lobe, atelectasis of left lung lobe, and an interstitial pattern. Follow-up x-rays on 12/21/21 revealed mildly progressive bronchointerstitial lung pattern and redundant aortic arch. Pet has since completed a course of Doxycycline. O reports no dyspnea, coughing, nor other respiratory signs. Pet is also diabetic. Had been well-controlled up until today.
Abnormal PE/Chem/CBC/UA Results: BG=576 Fructosamine=511

RADIOGRAPHIC STUDY OF THE THORAX

Radiographs of the thorax in three imaging planes are provided for review. Images are compared to the study dated 12/21/21

RADIOGRAPHIC FINDINGS

There is significant regression of the broncho-interstitial lung pattern – especially in the ventral lung field - , the lung parenchyma presents with the expected opacity and the pulmonary vessels can be followed up into the periphery of the lung.

No additional findings in comparison to the preceding radiographic study.

RADIOGRAPHIC DIAGNOSIS

- Significant regression of the broncho-interstitial lung pattern
- Redundant aortic arch
- Spondylosis deformans

INTERPRETATION OF THE FINDINGS & FURTHER RECOMMENDATIONS

The radiographic study presents complete remission of the lung pattern, there are no signs for persistent pneumonia/bronchopneumonia.



PATIENT

Teddy Moffitt

SPECIES

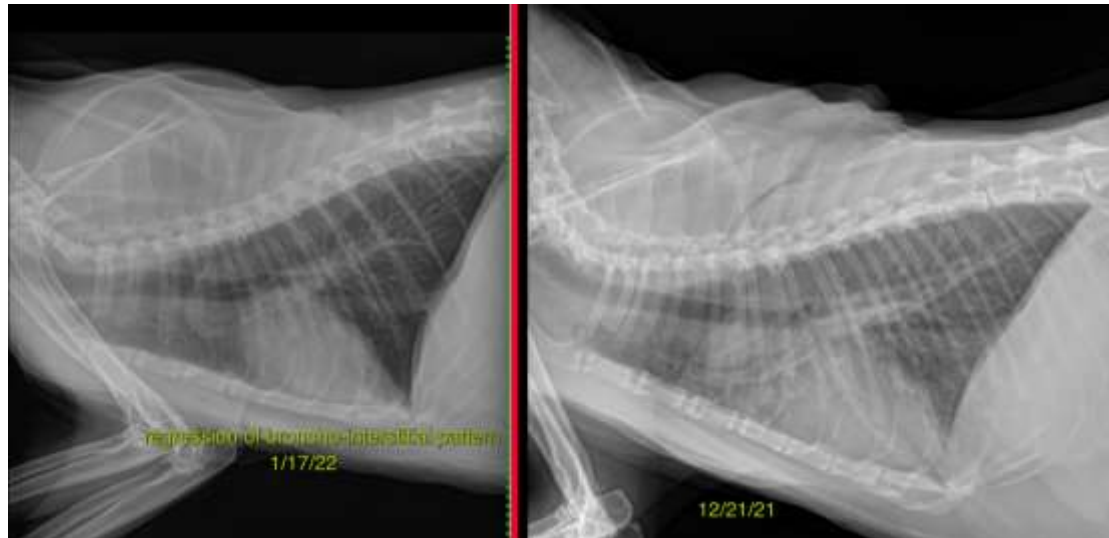
Feline

BREED

DSH

SEX

Male Neutered



AGE

13 Years

INTERPRETED BY

Sebastian Schaub, DVM
Dr. med. vet. DipECVDI

The information and recommendations provided are based on the images presented by the referring veterinarian. No evaluation can be communicated regarding pathology that was not visible in the image/video clips provided.

Thank you for this referral. If the clinical or image interpretation does not parallel your findings or if I can be of any further assistance please contact me.

HOSPITAL NAME

Long Valley Animal
Hospital

Sebastian Schaub, Sebastian Schaub, DVM, Dr. med. vet. DipECVDI
sebast.schaub@gmail.com

REFERRING VET

Russell Early

INVOICE

49627

DATE

1-17-22