

PATIENT

Rico Defalco

SPECIES

Canine

BREED

French Bulldog

SEX

Neutered Male

AGE

10 Years

WEIGHT

12 kg

INTERPRETED BY

Sebastian Schaub, DVM
Dr. med. vet. DipECVDI

IMAGING PERFORMED BY

Lisa S.

HOSPITAL NAME

ASC Oceanside

REFERRING VET

Dr. Infernuso

INVOICE

35459

DATE

1/16/26

PRESENTING CLINICAL SIGNS

History: Ataxia in the hind limbs, CP delayed, no pain Motor function positive, segmental reflexes HL increased spinal pain negative Ataxia / T3 L3 myelopathy rule out IVDD Heart Murmur Grade 1-2

COMPUTED TOMOGRAPHIC STUDY OF THE THORACIC & LUMBAR SPINE

A high resolution pre- and post-contrast CT study of the thoracic & lumbar spine is provided for review.

COMPUTED TOMOGRAPHIC FINDINGS

THE LAST RIB BEARING VERTEBRA IS COUNTED AS T13.

The intervertebral disc space C6/C7 presents v-shaped narrowing.

The vertebral endplates T11/T12 present moderate spondylosis formation.

The remainder of the osseous and soft tissue structures of the thoracic and lumbar spine reveal no abnormalities.

At the cranial aspect of the cranial extremity of the spleen, a well-defined, uniform soft tissue attenuating ovoid shaped lesion is appreciated, presenting a mild irregular contrast enhancement pattern, measuring 2.1 x 1.5 x 1.9 cm.

COMPUTED TOMOGRAPHIC DIAGNOSIS

- Discopathy C6/C7
- Spondylosis deformans T11/T12
- Soft tissue nodule cranial aspect of the cranial extremity of the spleen

INTERPRETATION OF THE FINDINGS & FURTHER RECOMMENDATIONS

The CT study reveals no abnormalities that do explain the paraparesis – there is no evidence of compressive myelopathy along the thoracic and lumbar spine – but isoattenuating extradural material can be missed. Workup can be complemented by a myelographic CT study or MRI study to screen for extradural or intradural lesions that may be missed by the current CT series.

The soft tissue nodule at the between the cranial extremity of the spleen and the stomach can present a Splenunculus or less likely enlarged lymph node.



PATIENT

Rico Defalco

SPECIES

Canine

BREED

French Bulldog

SEX

Neutered Male

AGE

10 Years

WEIGHT

12 kg

INTERPRETED BY

Sebastian Schaub, DVM
Dr. med. vet. DipECVDI

IMAGING PERFORMED BY

Lisa S.

HOSPITAL NAME

ASC Oceanside

REFERRING VET

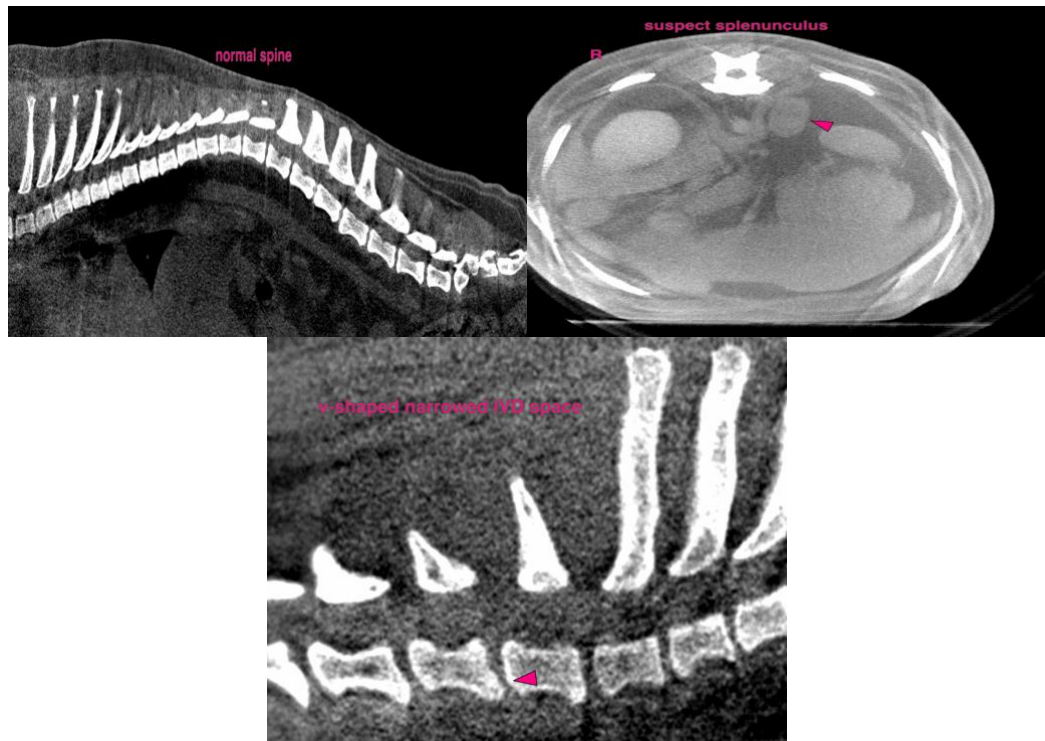
Dr. Infernuso

INVOICE

35459

DATE

1/16/26



The information and recommendations provided are based on the images presented by the referring veterinarian/sonographer. No evaluation can be communicated regarding pathology that was not visible in the image/video clips provided.

Thank you for this referral. If the clinical or image interpretation does not parallel your findings or if I can be of any further assistance please contact me.

Sebastian Schaub, DVM, Dr. med. vet. DipECVDI
info@sonopath.com