

**PATIENT**

Yogi Vicente

PRESENTING CLINICAL SIGNS

Acute lameness after running after squirrel.. Right hind...
Abnormal PE/Chem/CBC/UA Results: WNL

SPECIES

Canine

RADIOGRAPHIC STUDY OF THE PELVIS AND RIGHT STIFLE JOINT

Radiographs of the pelvis and right stifle joint in two imaging planes are provided for review.

BREED

Mixed

RADIOGRAPHIC FINDINGS

There is a generalized chondrodystrophic conformation of the osseous structures.

SEX

Male/N

The osseous and surrounding soft tissue structures of the pelvis are within normal limits. The coxofemoral joints are mildly incongruent and mild osteophyte new bone formation is seen at the transition of the right femoral head & neck.

The osseous margins of the right stifle joint are smooth. There is a mild increased intracapsular soft tissue swelling, distorting the infrapatellar fat-pad cranially and the fascial plane caudally. The patella is in situ.

AGE

7 Years

RADIOGRAPHIC DIAGNOSIS

- Mild articular swelling right stifle joint
- Mild degenerative osteoarthritis right coxofemoral joints

INTERPRETED BY

Sebastian Schaub, DVM
Dr. med. vet. DipECVDI

INTERPRETATION OF THE FINDINGS & FURTHER RECOMMENDATIONS

The mild joint effusion of the right stifle joint can be traumatic, degenerative or inflammatory in origin – the first two are considered most likely. Check clinically if instability of the right stifle joint is present – positive tibial compression test/positive drawer sign, if applicable under general anesthesia. If clinical findings are equivocal, consider a clinical trial with NSAID and rest and reevaluating after 2-3 weeks.

HOSPITAL NAME

New Bridge
Veterinary Practice

REFERRING VET

Dr. Abina Glennon

INVOICE

49628

DATE

1-15-22



PATIENT

Yogi Vicente

SPECIES

Canine

BREED

Mixed

SEX

Male/N

AGE

7 Years

INTERPRETED BY

Sebastian Schaub, DVM
Dr. med. vet. DipECVDI

HOSPITAL NAME

New Bridge
Veterinary Practice

REFERRING VET

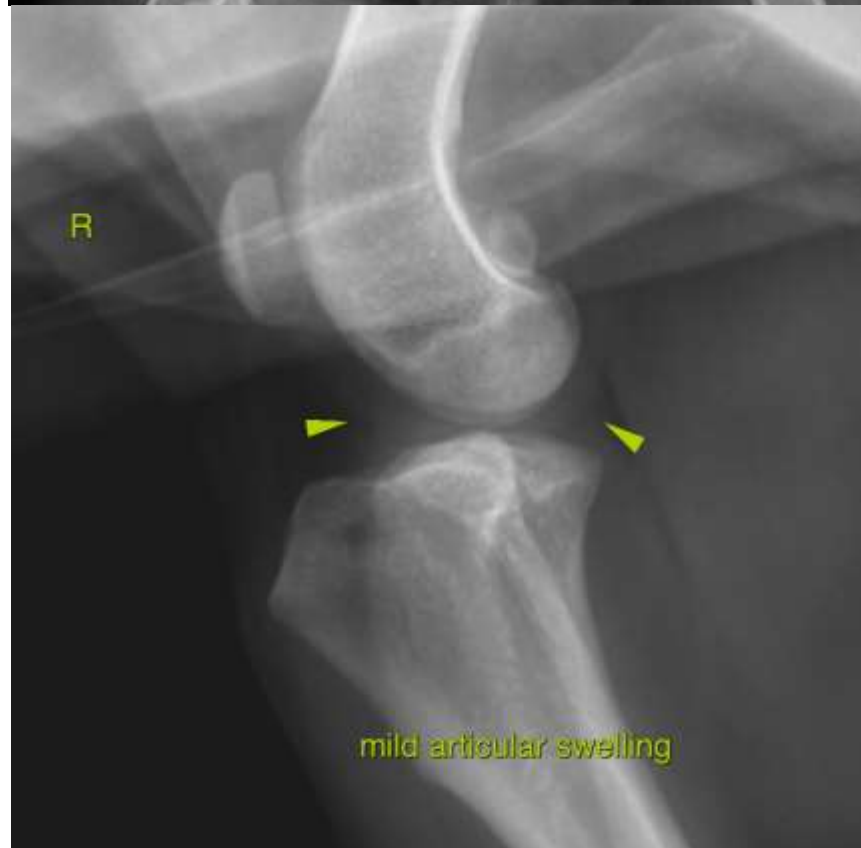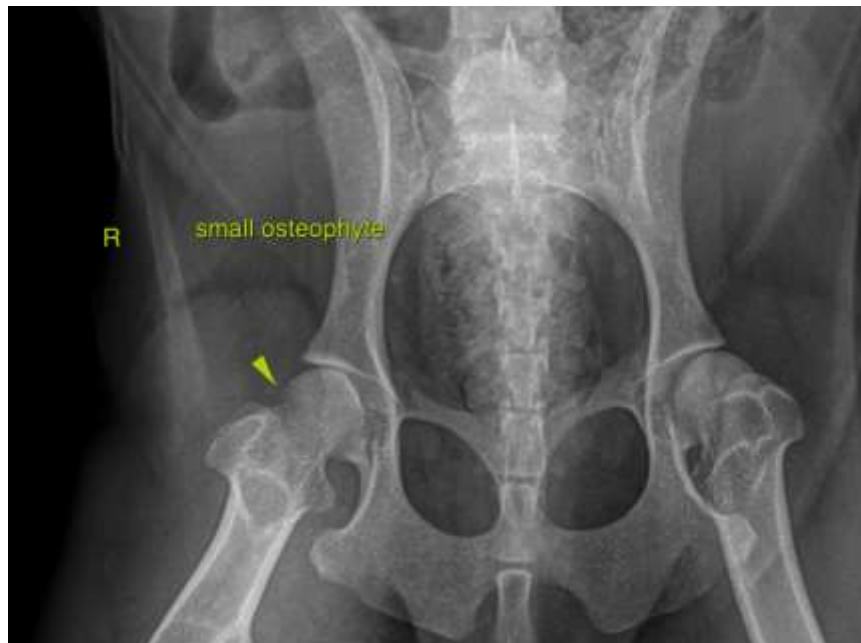
Dr. Abina Glennon

INVOICE

49628

DATE

1-15-22





PATIENT

Yogi Vicente

SPECIES

Canine

BREED

Mixed

SEX

Male/N

AGE

7 Years

INTERPRETED BY

Sebastian Schaub, DVM
Dr. med. vet. DipECVDI

HOSPITAL NAME

New Bridge
Veterinary Practice

REFERRING VET

Dr. Abina Glennon

INVOICE

49628

DATE

1-15-22

The information and recommendations provided are based on the images presented by the referring veterinarian. No evaluation can be communicated regarding pathology that was not visible in the image/video clips provided.

Thank you for this referral. If the clinical or image interpretation does not parallel your findings or if I can be of any further assistance please contact me.

Sebastian Schaub, Sebastian Schaub, DVM, Dr. med. vet. DipECVDI
sebast.schaub@gmail.com