



PATIENT

Winnie Sol

SPECIES

Canine

BREED

Golden Retriever

SEX

Fi

AGE

7M

WEIGHT

18.8kg

INTERPRETED BY

Sebastian Schaub, DVM
Dr. med. vet.
DipECVDI

IMAGING PERFORMED BY

Janice

HOSPITAL NAME

Bridgwater Veterinary
Hospital and Wellness
Centre

REFERRING VET

Dr. J. Tait

INVOICE

73325

DATE

1-14-26

PRESENTING CLINICAL SIGNS

2 day history of acute lethargy, fever, and neck pain.
Abnormal PE/Chem/CBC/UA Results: mild puppy anemia inflammatory leukogram chem nsf_

COMPUTED TOMOGRAPHY OF THE SKULL & NECK

A high resolution pre- and post-contrast CT study of the skull and neck is provided for review.

COMPUTED TOMOGRAPHIC FINDINGS

The pictured parts of the dentition are complete and unremarkable in all jaw quadrants.

The nasal cavity presents the expected aerated spaces between thin & even conchae and turbinates with smooth mucosal lining.

Both temporomandibular joints present congruent joint spaces with even subchondral bone surfaces and are considered within normal limits.

Both tympanic bullae are aerated, the mucosal lining is not seen, the bony wall is smooth and thin. The external ear canals are within normal limits.

The brain presents no deviation from normal anatomy and symmetry. The brain parenchyma is homogeneous and within normal limits for attenuation and distribution of contrast enhancement. The ventricular system is non-dilated and symmetric.

The submandibular and medial retropharyngeal lymph nodes are small and elongated with a normal short-to-long-axis-ratio is < 0.5, the attenuation and contrast enhancement pattern is uniform.

COMPUTED TOMOGRAPHIC DIAGNOSIS

- Normal skull
- Normal neck

INTERPRETATION OF THE FINDINGS & FURTHER RECOMMENDATIONS

The CT study reveals no abnormalities and an underlying cause for the presenting clinical signs cannot be specified. Given the presenting clinical signs in this juvenile patient, steroid responsive meningitis arteritis may be a potential. Workup can be complemented by a CSF tap including evaluation of IgA values.



PATIENT

Winnie Sol

SPECIES

Canine

BREED

Golden Retriever

SEX

Fi

AGE

7M

WEIGHT

18.8kg

INTERPRETED BY

Sebastian Schaub, DVM
Dr. med. vet.
DipECVDI

IMAGING PERFORMED BY

Janice

HOSPITAL NAME

Bridgwater Veterinary
Hospital and Wellness
Centre

REFERRING VET

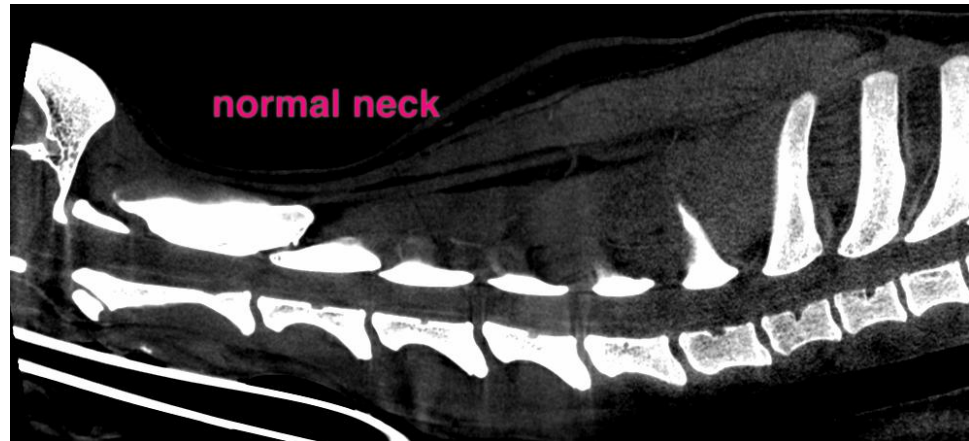
Dr. J. Tait

INVOICE

73325

DATE

1-14-26



The information and recommendations provided are based on the images presented by the referring veterinarian/sonographer. No evaluation can be communicated regarding pathology that was not visible in the image/video clips provided.

Thank you for this referral. If the clinical or image interpretation does not parallel your findings or if I can be of any further assistance please contact me.

Sebastian Schaub, Sebastian Schaub, DVM, Dr. med. vet. DipECVDI
info@sonopath.com