



PATIENT PRESENTING CLINICAL SIGNS

Rocket Garcia History: Patient presents for a COHAT. A survey CT of the skull with emphasis on the dental arcade is submitted for review.

SPECIES COMPUTED TOMOGRAPHIC STUDY OF THE SKULL

Canine A high-resolution plain CT study of the skull is provided for review.

COMPUTED TOMOGRAPHIC FINDINGS

BREED

Schipperke

The tooth elements 107, 110, 209, 303, 402, 410 and 411 are absent. The tooth elements 108, 109, 305, 306 and 308 present a moderate widening of the periodontal space. Triadan 204 & 304 present a mild to moderate widening of the periodontal space in the proximal segment. A moderate horizontal bone loss is seen level with the lower incisors.

SEX

Neutered Male

The nasal cavity presents the expected aerated spaces between thin & even conchae and turbinates with smooth mucosal lining.

AGE

10 Years 10 Months

Both temporomandibular joints present congruent joint spaces with even subchondral bone surfaces and are considered within normal limits.

Both tympanic bullae are aerated, the mucosal lining is not seen, the bony wall is smooth and thin. The external ear canals are within normal limits.

COMPUTED TOMOGRAPHIC DIAGNOSIS

INTERPRETED BY

Sebastian Schaub,
DVM Dr. med. vet.
DipECVDI

- Moderate periodontal disease 108, 109, 305, 306 and 308
- Horizontal bone loss level with the mandibular incisors bilaterally
- Mild to moderate periodontal disease 204 & 304
- Absent triadan 107, 110, 209, 303, 402, 410 and 411

HOSPITAL NAME

South Bay AH

INTERPRETATION OF THE FINDINGS & FURTHER RECOMMENDATIONS

There is evidence of periodontal disease of multiple teeth – see above – and extraction at least of the affected premolar and molar teeth is recommended.

REFERRING VET

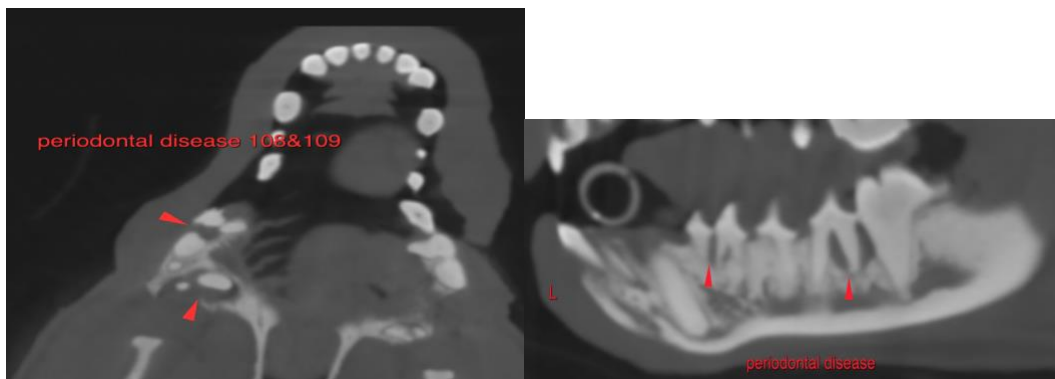
Ravinder Atwal

INVOICE

13430

DATE

1/14/22





PATIENT

Rocket Garcia

The information and recommendations provided are based on the images presented by the referring veterinarian. No evaluation can be communicated regarding pathology that was not visible in the image/video clips provided.

SPECIES

Canine

Thank you for this referral. If the clinical or image interpretation does not parallel your findings or if I can be of any further assistance please contact me.

Sebastian Schaub, Sebastian Schaub, DVM, Dr. med. vet. DipECVDI
sebast.schaub@gmail.com

BREED

Schipperke

SEX

Neutered Male

AGE

10 Years 10 Months

INTERPRETED BY

Sebastian Schaub,
DVM Dr. med. vet.
DipECVDI

HOSPITAL NAME

South Bay AH

REFERRING VET

Ravinder Atwal

INVOICE

13430

DATE

1/14/22