



PATIENT

Cooper Roritsen

SPECIES

Canine

BREED

Labrador

SEX

MN

AGE

5

WEIGHT

50

INTERPRETED BY

Sebastian Schaub, DVM
Dr. med. vet.
DipECVDI

IMAGING PERFORMED BY

Eamon

HOSPITAL NAME

Belconnen Veterinary
Centre

REFERRING VET

Eamon

INVOICE

73323

DATE

1-13-26

PRESENTING CLINICAL SIGNS

LF lameness >1yr suspect nidus L elbow
Abnormal PE/Chem/CBC/UA Results: cbc/chem/t4 normal march 25

COMPUTED TOMOGRAPHY OF THE FRONT LIMBS

A pre- and post-contrast CT study of the front limbs in a bone and soft tissue reconstruction is provided for review.

COMPUTED TOMOGRAPHIC FINDINGS

Level with the intervertebral disc space C7/T1, mineralized disc material is protruding into the left ventral aspect of the vertebral canal, occupying approximately $\leq 10\%$ of the cross-sectional area of the vertebral canal at the same level.

Both shoulder joints present smooth margins of the periarticular bones and the surrounding soft tissue structures are within normal limits.

The periarticular bones of both elbow joints present mild to moderate osteophyte new bone formation. The medial coronoid process of both elbow joints is irregular and has a heterogeneous density, L>R. The joint space of both elbow joints presents very mild incongruity.

Along the dorsal aspect of the carpal bones, very mild osteophyte new bone formation is seen. Between the proximal segment of the 1st and 2nd metacarpal bone, bridging exostosis formation is seen.

COMPUTED TOMOGRAPHIC DIAGNOSIS

- Coronoid disease elbow joint bilaterally, L>R
- Osteoarthritis elbow joint bilaterally
- Exostosis formation dorsal aspect 1st and 2nd metacarpal bone bilaterally
- Very mild osteoarthritis carpal joints

INTERPRETATION OF THE FINDINGS & FURTHER RECOMMENDATIONS

The CT study is consistent with bilateral elbow dysplasia and secondary degenerative joint disease of the elbow joints. Arthroscopy/arthrotomy would be ideal to revise the elbow joints and remove the osseous fragment/nonvital tip of the medial coronoid process to avoid further damage.



PATIENT

Cooper Roritsen

SPECIES

Canine

BREED

Labrador

SEX

MN

AGE

5

WEIGHT

50

INTERPRETED BY

Sebastian Schaub, DVM
Dr. med. vet.
DipECVDI

IMAGING PERFORMED BY

Eamon

HOSPITAL NAME

Belconnen Veterinary
Centre

REFERRING VET

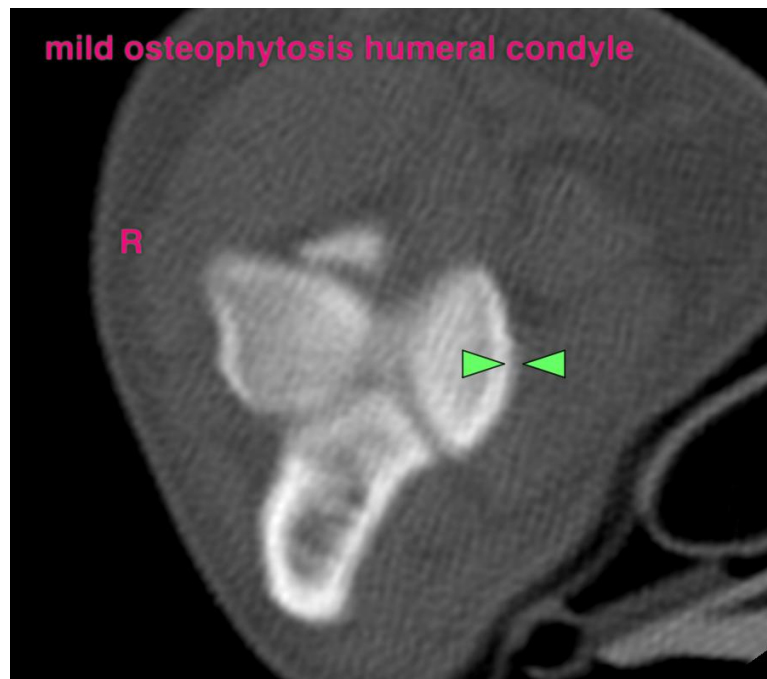
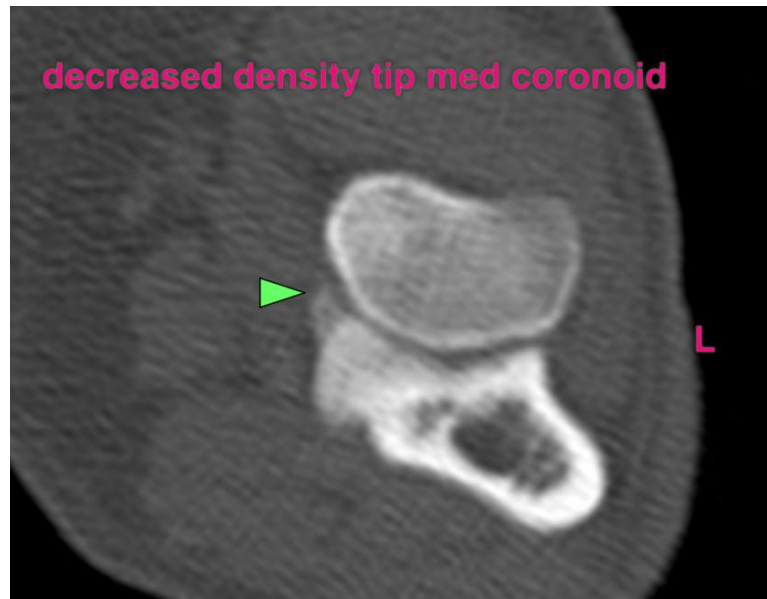
Eamon

INVOICE

73323

DATE

1-13-26



The information and recommendations provided are based on the images presented by the referring veterinarian/sonographer. No evaluation can be communicated regarding pathology that was not visible in the image/video clips provided.

Thank you for this referral. If the clinical or image interpretation does not parallel your findings or if I can be of any further assistance please contact me.

Sebastian Schaub, Sebastian Schaub, DVM, Dr. med. vet. DipECVDI
info@sonopath.com