



PATIENT PRESENTING CLINICAL SIGNS

Tula Fawley Healthy seeming dog. Has asymmetrical hard swelling on Rt side bridge of nose. Do obvious dental cause. R/O cancer, abscess?

SPECIES COMPUTED TOMOGRAPHY OF THE SKULL

Canine A high resolution pre- and post-contrast CT study of the skull is provided for review.

BREED COMPUTED TOMOGRAPHIC FINDINGS

Shepherd X The tooth element 207 is absent. Triadan 104 presents a moderate widening of the periodontal space with perforation of the alveolar crest laterally – a moderate subcutaneous swelling is seen at the same level, as well as mild intranasal swelling. The remainder of the nasal cavity presents the expected aerated spaces between thin & even conchae and turbinates with smooth mucosal lining. The soft tissues at the dorsal aspect of the nose are overexposed and burned out.

SEX

FS Both temporomandibular joints present congruent joint spaces with even subchondral bone surfaces and are considered within normal limits.

AGE

7 Years Both tympanic bullae are aerated, the mucosal lining is not seen, the bony wall is smooth and thin. The external ear canals are within normal limits.

INTERPRETED BY

Sebastian Schaub, DVM
Dr. med. vet. DipECVDI

The brain presents no deviation from normal anatomy and symmetry. The brain parenchyma is homogeneous and within normal limits for attenuation and distribution of contrast enhancement. The ventricular system is non-dilated and symmetric.

The submandibular and medial retropharyngeal lymph nodes are small and elongated with a normal short-to-long-axis-ratio is < 0.5, the attenuation and contrast enhancement pattern is uniform.

HOSPITAL NAME

Bridgwater
Veterinary Hospital
and Wellness Centre

COMPUTED TOMOGRAPHIC DIAGNOSIS

- Periodontal abscess formation triadan 104 with local subcutaneous swelling and mild intranasal mucosal swelling
- Absent triadan 207

REFERRING VET

Dr. Heather Wilton

INTERPRETATION OF THE FINDINGS & FURTHER RECOMMENDATIONS

The swelling at the right side of the nose, level with triadan 104 is very likely a sequela to periodontal abscess formation of triadan 104. There is evidence of mild local rhinitis as well. Recommend extraction of the affected dental element. Sampling from the alveolar crest for pathology can be used to rule out neoplastic disease completely.

INVOICE

49555

DATE

1-13-22



PATIENT

Tula Fawley

SPECIES

Canine

BREED

Shepherd X

SEX

FS

AGE

7 Years

INTERPRETED BY

Sebastian Schaub, DVM
Dr. med. vet. DipECVDI

HOSPITAL NAME

Bridgwater
Veterinary Hospital
and Wellness Centre

REFERRING VET

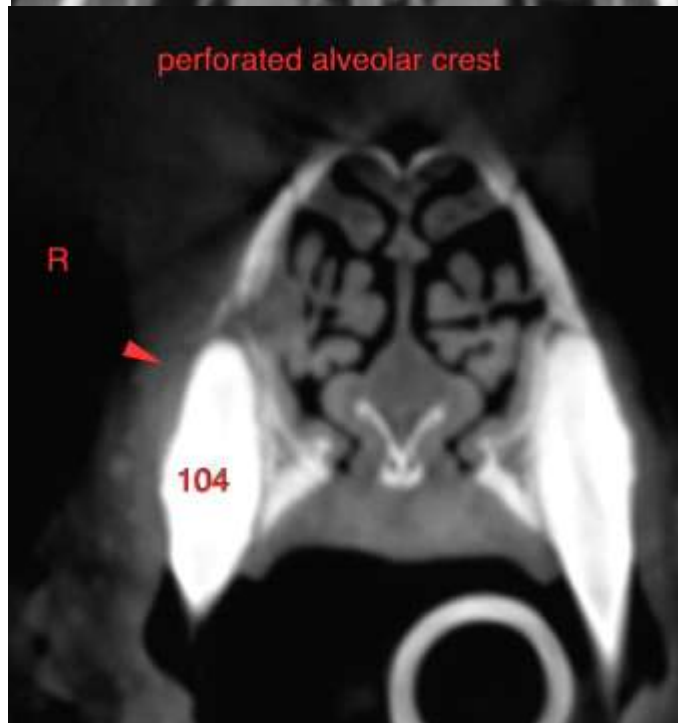
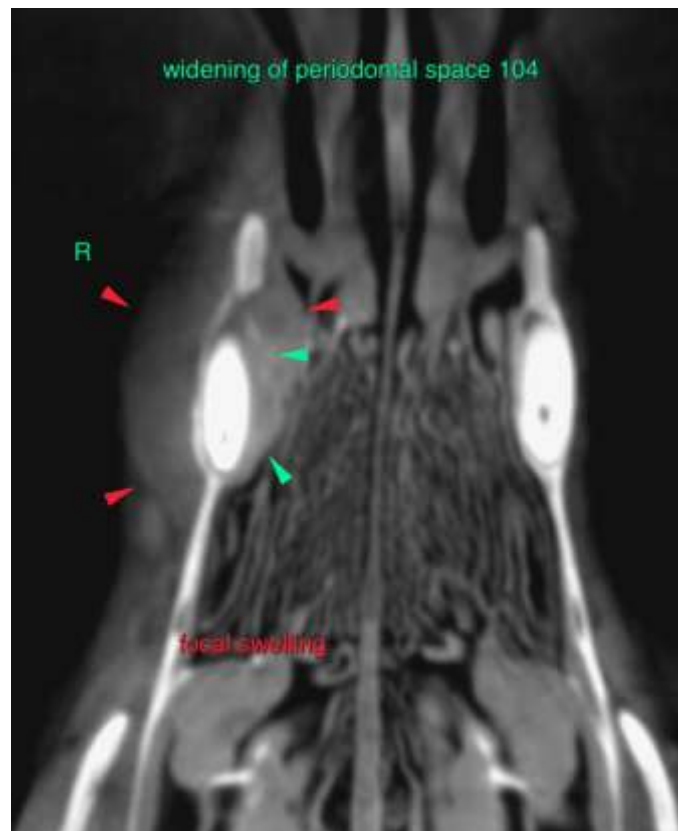
Dr. Heather Wilton

INVOICE

49555

DATE

1-13-22





PATIENT

Tula Fawley

SPECIES

Canine

The information and recommendations provided are based on the images presented by the referring veterinarian. No evaluation can be communicated regarding pathology that was not visible in the image/video clips provided.

BREED

Shepherd X

Thank you for this referral. If the clinical or image interpretation does not parallel your findings or if I can be of any further assistance please contact me.

Sebastian Schaub, Sebastian Schaub, DVM, Dr. med. vet. DipECVDI
sebast.schaub@gmail.com

SEX

FS

AGE

7 Years

INTERPRETED BY

Sebastian Schaub, DVM
Dr. med. vet. DipECVDI

HOSPITAL NAME

Bridgwater
Veterinary Hospital
and Wellness Centre

REFERRING VET

Dr. Heather Wilton

INVOICE

49555

DATE

1-13-22