



PATIENT

Sasha Schreibman

PRESENTING CLINICAL SIGNS

Multiple liver masses

SPECIES

Canine

COMPUTED TOMOGRAPHY OF THE ABDOMEN

A high resolution pre- and post-contrast CT study of the abdomen is provided for review.

BREED

Cockapoo

COMPUTED TOMOGRAPHIC FINDINGS

The serosal fat presents normal attenuation behavior. There is no evidence of peritoneal effusion or peritonitis.

SEX

Female Spayed

Both kidneys present within normal limits for size, shape and organ architecture. After contrast administration a bilaterally symmetric and uniform nephro- and pyelogram is noted.

The adrenal glands are within normal limits for size, shape and organ architecture.

The spleen presents with normal shape, even surface, uniformly attenuating parenchyma and homogeneous contrast enhancement, unremarkable.

AGE

13 Years

Likely originating from the dorsal aspect of the right lateral liver lobe, a multilobulated, homogeneous soft tissue attenuating and heterogeneous contrast enhancing mass is seen, measuring 10.1 x 7.9 x 12.9 cm in size. The mass is extending caudally, displacing the caudate process of the caudate liver lobe medially and ventrally. The pylorus and proximal duodenum are displaced ventrally by the mass effect. A second mass presenting a mild heterogeneous contrast enhancement pattern is seen in the dorsal aspect of the left lateral liver lobe, measuring 4.2 x 3.4 x 4.7 cm in size, mildly protruding beyond the hepatic surface laterally. The left medial liver lobe presents a mild heterogeneous contrast enhancement pattern with convex bulging of the surface.

INTERPRETED BY

Sebastian Schaub, DVM
Dr. med. vet. DipECVDI

HOSPITAL NAME

Mobile Pet Imaging

The pancreas is evenly contoured, the pancreatic parenchyma is homogeneous and presents uniform contrast enhancement.

The position, delineation, wall and content of the gastrointestinal tract are considered within normal limits throughout.

REFERRING VET

Meaux

The intervertebral disc L2/L3 is mildly protruding into the vertebral canal. The lumbosacral intervertebral disc is moderately protruding into the vertebral canal, displacing the caudal equina fibers dorsally. The pictured parts of both stifle joints present moderate osteophyte new bone formation.

INVOICE

49588

COMPUTED TOMOGRAPHIC DIAGNOSIS

- Multiple hepatic masses with the largest likely originating from the right lateral liver lobe and secundar mass in the left lateral liver lobe
- Generalized significant hepatomegaly
- Degenerative lumbosacral stenosis
- Degenerative osteoarthritis stifle joints bilaterally
- Mild intervertebral disc protrusion L2/L3 without compressive myelopathy

DATE

1-13-22



PATIENT

Sasha Schreibman

SPECIES

Canine

BREED

Cockapoo

SEX

Female Spayed

AGE

13 Years

INTERPRETED BY

Sebastian Schaub, DVM
Dr. med. vet. DipECVDI

HOSPITAL NAME

Mobile Pet Imaging

REFERRING VET

Meaux

INVOICE

49588

DATE

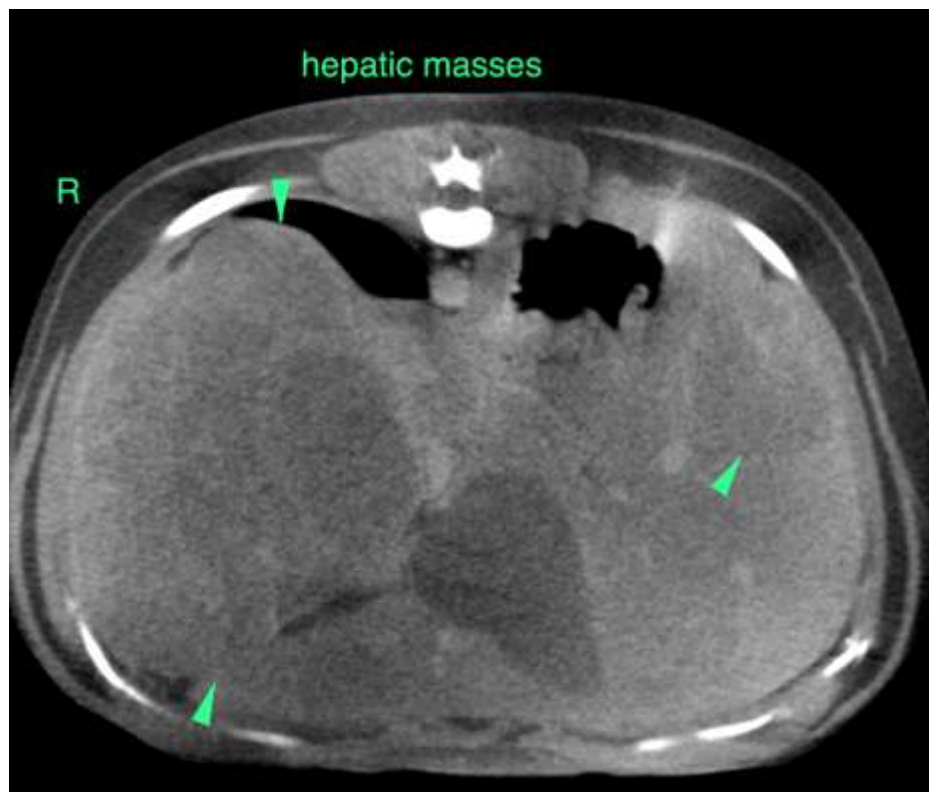
1-13-22

INTERPRETATION OF THE FINDINGS & FURTHER RECOMMENDATIONS

The findings fit the history of multiple hepatic mass lesions with the largest, likely originating from the right lateral liver lobe and a second mass in the left lateral liver lobe. Complete surgical resection will warrant lobectomy of the respective liver lobes, it might be challenging but appears feasible.

Potentials for the hepatomegaly include metabolic hepatic disease, hepatitis or diffuse neoplastic infiltration.

No additional clinically relevant abnormalities are appreciated.





PATIENT

Sasha Schreibman

SPECIES

Canine

BREED

Cockapoo

SEX

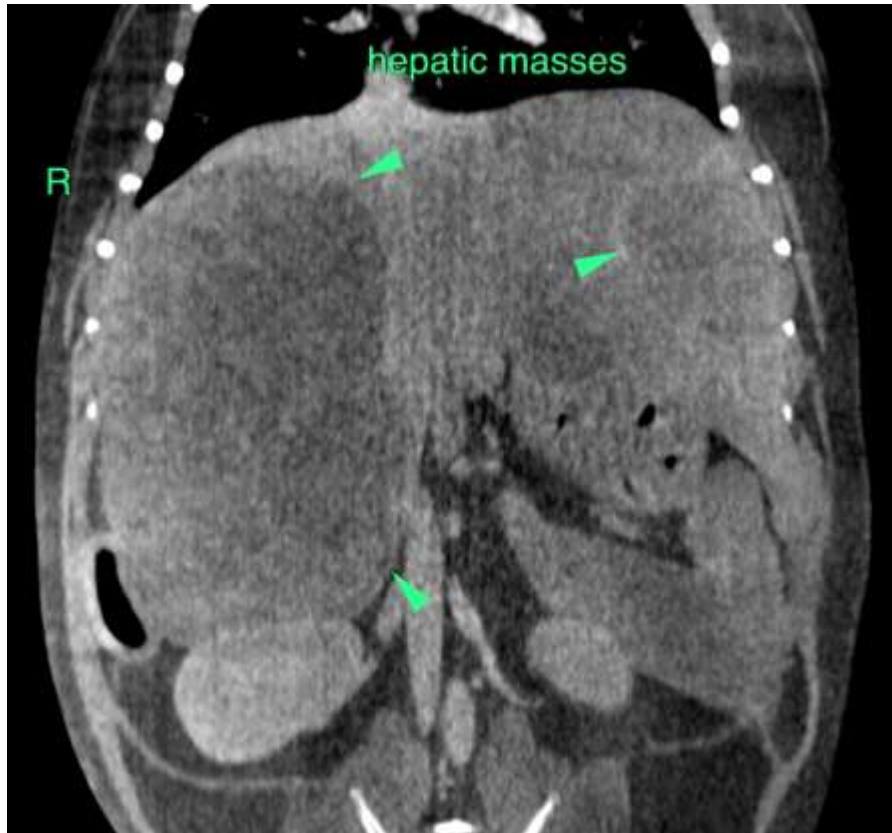
Female Spayed

AGE

13 Years

INTERPRETED BY

Sebastian Schaub, DVM
Dr. med. vet. DipECVDI



HOSPITAL NAME

Mobile Pet Imaging

REFERRING VET

Meaux

INVOICE

49588

DATE

1-13-22

The information and recommendations provided are based on the images presented by the referring veterinarian. No evaluation can be communicated regarding pathology that was not visible in the image/video clips provided.

Thank you for this referral. If the clinical or image interpretation does not parallel your findings or if I can be of any further assistance please contact me.

Sebastian Schaub, Sebastian Schaub, DVM, Dr. med. vet. DipECVDI
sebast.schaub@gmail.com