



**PATIENT PRESENTING CLINICAL SIGNS**

Toby Roca Upper respiratory congestion, swelling on skull medial to Left eye.

**COMPUTED TOMOGRAPHY OF THE SKULL**

**SPECIES** A high resolution pre- and post-contrast CT study of the skull is provided for review.

Canine **COMPUTED TOMOGRAPHIC FINDINGS**

The pictured parts of the dentition are complete.

**BREED** The left nasal cavity is occupied by an expansile soft tissue attenuating and heterogeneous contrast enhancing mass. The left maxillary bone, left palatine bone and left frontal bone present extensive osteolytic lesions – protruding into the subcutaneous tissue at the dorsal aspect of the nose/frontal sinus and submucosa of the hard palate. The osseous lamella between the frontal sinus and the cranial fossa is perforated.

**SEX** Both temporomandibular joints present congruent joint spaces with even subchondral bone surfaces and are considered within normal limits.

Intact Male

Both tympanic bullae are aerated, the mucosal lining is not seen, the bony wall is smooth and thin. The external ear canals are within normal limits.

**AGE**

10 Years, 1 Month

The brain presents no deviation from normal anatomy and symmetry. The brain parenchyma is homogeneous and within normal limits for attenuation and distribution of contrast enhancement. The ventricular system is non-dilated and symmetric.

**INTERPRETED BY**

Sebastian Schaub, DVM  
Dr. med. vet. DipECVDI

The submandibular and medial retropharyngeal lymph nodes are small and elongated with a normal short-to-long-axis-ratio is < 0.5, the attenuation and contrast enhancement pattern is uniform.

**HOSPITAL NAME**

Mobile Pet Imaging

Originating from the left and right thyroid gland, an ill-defined, uniform soft tissue attenuating and heterogeneous contrast enhancing ovoid shaped mass is seen respectively (L>R). The left thyroid mass is measuring approximately 5.9 x 3.5 x 7.5 cm in size. The trachea is deviated dorsally and mildly to the right by the mass effect.

**COMPUTED TOMOGRAPHIC DIAGNOSIS**

**REFERRING VET**

Meaux

- Left sided biologically aggressive nasal soft tissue neoplasia with polyostotic aggressive osteolytic lesions and perforation of the cranial fossa
- Thyroid mass lesions bilaterally

**INTERPRETATION OF THE FINDINGS & FURTHER RECOMMENDATIONS**

**INVOICE**

56152

The nasal mass is consistent with primary nasal neoplasia, perforating the osseous lining of the nasal cavity – explain in the swelling along the dorsal aspect of the nose/skull. The nasal mass is perforating the cranial fossa. Differentials include adenocarcinoma, squamous cell carcinoma, transitional cell carcinoma, lymphosarcoma, other. FNA sampling of the subcutaneous swelling or rhinoscopy including biopsy can be used as advanced diagnostic tests. Based on the results of the advanced diagnostic tests, the chances of radiation therapy can be discussed with oncologist. The Adam tumor stage is T4.

**DATE**

1-12-23

There is evidence of mass lesions originating from the thyroid gland bilaterally, highly concerning for neoplastic transformation as a second entity, such as thyroid carcinoma or neuroendocrine tumor of



**PATIENT** different origin. As there is bilateral enlargement of the thyroid glands, goiter or thyroiditis are theoretical differentials. Recommend FNA sampling as advanced diagnostic tool.

Toby Roca Consider full tumor staging.

**SPECIES**

Canine

**BREED**

Beagle

**SEX**

Intact Male

**AGE**

10 Years, 1 Month

**INTERPRETED BY**

Sebastian Schaub, DVM  
Dr. med. vet. DipECVDI

**HOSPITAL NAME**

Mobile Pet Imaging

**REFERRING VET**

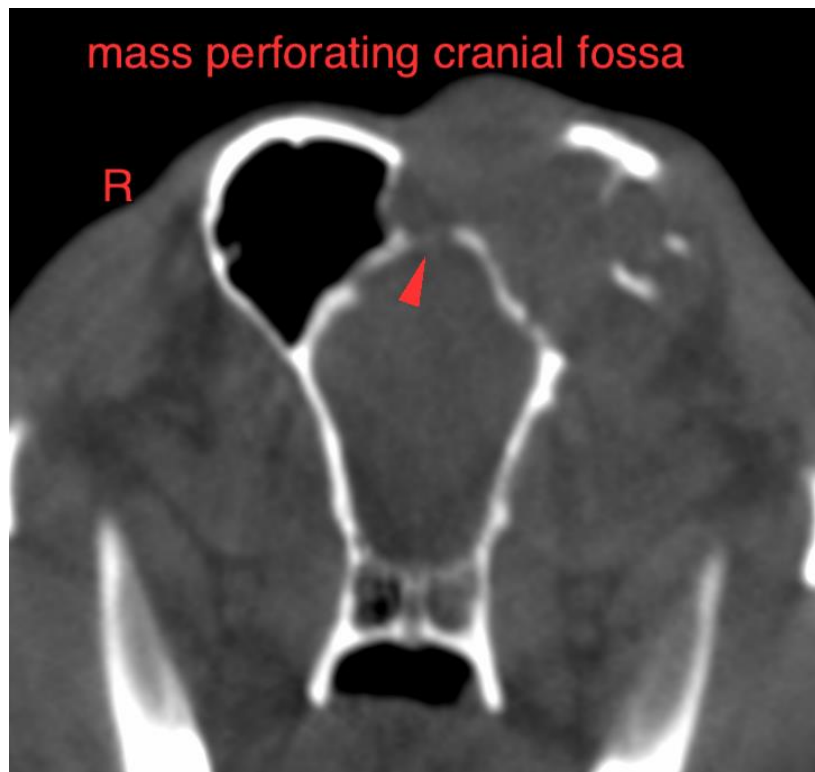
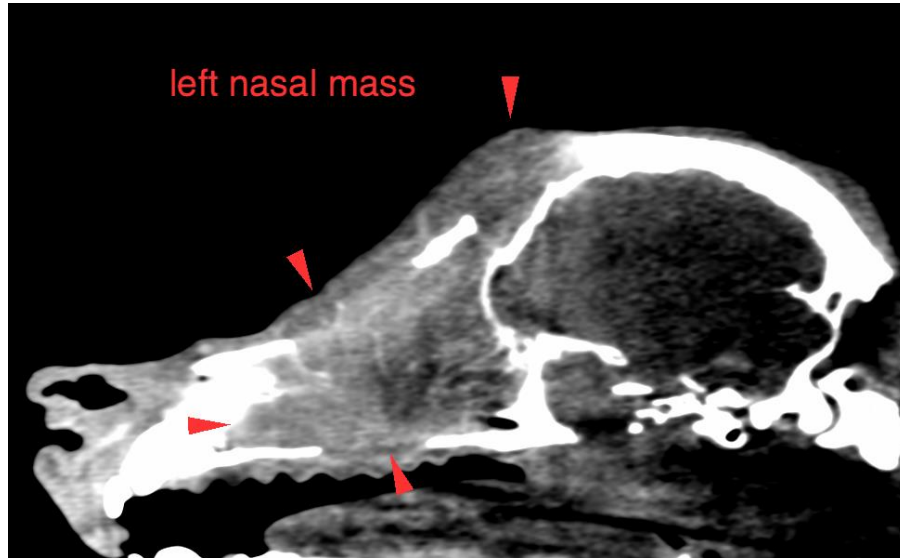
Meaux

**INVOICE**

56152

**DATE**

1-12-23





**PATIENT**

Toby Roca

**SPECIES**

Canine

**BREED**

Beagle

**SEX**

Intact Male

**AGE**

10 Years, 1 Month

**INTERPRETED BY**

Sebastian Schaub, DVM  
Dr. med. vet. DipECVDI

**HOSPITAL NAME**

Mobile Pet Imaging

**REFERRING VET**

Meaux

The information and recommendations provided are based on the images presented by the referring veterinarian/sonographer. No evaluation can be communicated regarding pathology that was not visible in the image/video clips provided.

Thank you for this referral. If the clinical or image interpretation does not parallel your findings or if I can be of any further assistance please contact me.

**Sebastian Schaub**, Sebastian Schaub, DVM, Dr. med. vet. DipECVDI  
sebast.schaub@gmail.com

**INVOICE**

56152

**DATE**

1-12-23

