



**PATIENT PRESENTING CLINICAL SIGNS**

Garth Ru4me Rescue Had URI signs mid November and was started on clavamox. Developed left head tilt 11/30 (about 1 week into treatment). Suspected to have polyp in left middle ear. Treated with course of azithromycin in dec, URI signs resolved. Persistent head tilt despite prednisolone

**SPECIES COMPUTED TOMOGRAPHY OF THE SKULL**

Feline A high resolution pre- and post-contrast CT study of the skull is provided for review.

**COMPUTED TOMOGRAPHIC FINDINGS**

**BREED**

The dentition is unremarkable with erupting permanent teeth.

**DSH**

The nasal cavity presents the expected aerated spaces between thin & even conchae and turbinates with smooth mucosal lining.

**SEX**

Both temporomandibular joints present congruent joint spaces with even subchondral bone surfaces and are considered within normal limits.

**Neutered Male**

The right tympanic bulla is aerated, the mucosal lining is not seen, the bony wall is smooth and thin. The left tympanic bulla is filled with soft tissue attenuating material; the wall is mildly thickened and smooth. The osseous labyrinth of the left inner ear presents moth eaten osteolytic lesions in the lateral aspect. The external ear canals are within normal limits.

**AGE**

**4 Months**

The brain presents no deviation from normal anatomy and symmetry. The brain parenchyma is homogeneous and within normal limits for attenuation and distribution of contrast enhancement. The ventricular system is non-dilated and symmetric.

**INTERPRETED BY**

Sebastian Schaub, DVM  
Dr. med. vet. DipECVDI

The submandibular and medial retropharyngeal lymph nodes are small and elongated with a normal short-to-long-axis-ratio is < 0.5, the attenuation and contrast enhancement pattern is uniform.

**HOSPITAL NAME**

Mobile Pet Imaging

**COMPUTED TOMOGRAPHIC DIAGNOSIS**

- Left sided otitis media & interna.
- No evidence of inflammatory polyp formation

**REFERRING VET**

Meaux

**INTERPRETATION OF THE FINDINGS & FURTHER RECOMMENDATIONS**

The CT study is consistent with left sided otitis media and accompanying otitis media; the findings are a plausible source for the head tilt. If clinical signs persist under empirical therapy, surgical management of the left sided otitis media might be considered.

**INVOICE**

56150

**DATE**

1-12-23



**PATIENT**

Garth Ru4me Rescue

**SPECIES**

Feline

**BREED**

DSH

**SEX**

Neutered Male

**AGE**

4 Months

**INTERPRETED BY**

Sebastian Schaub, DVM  
Dr. med. vet. DipECVDI

**HOSPITAL NAME**

Mobile Pet Imaging

**REFERRING VET**

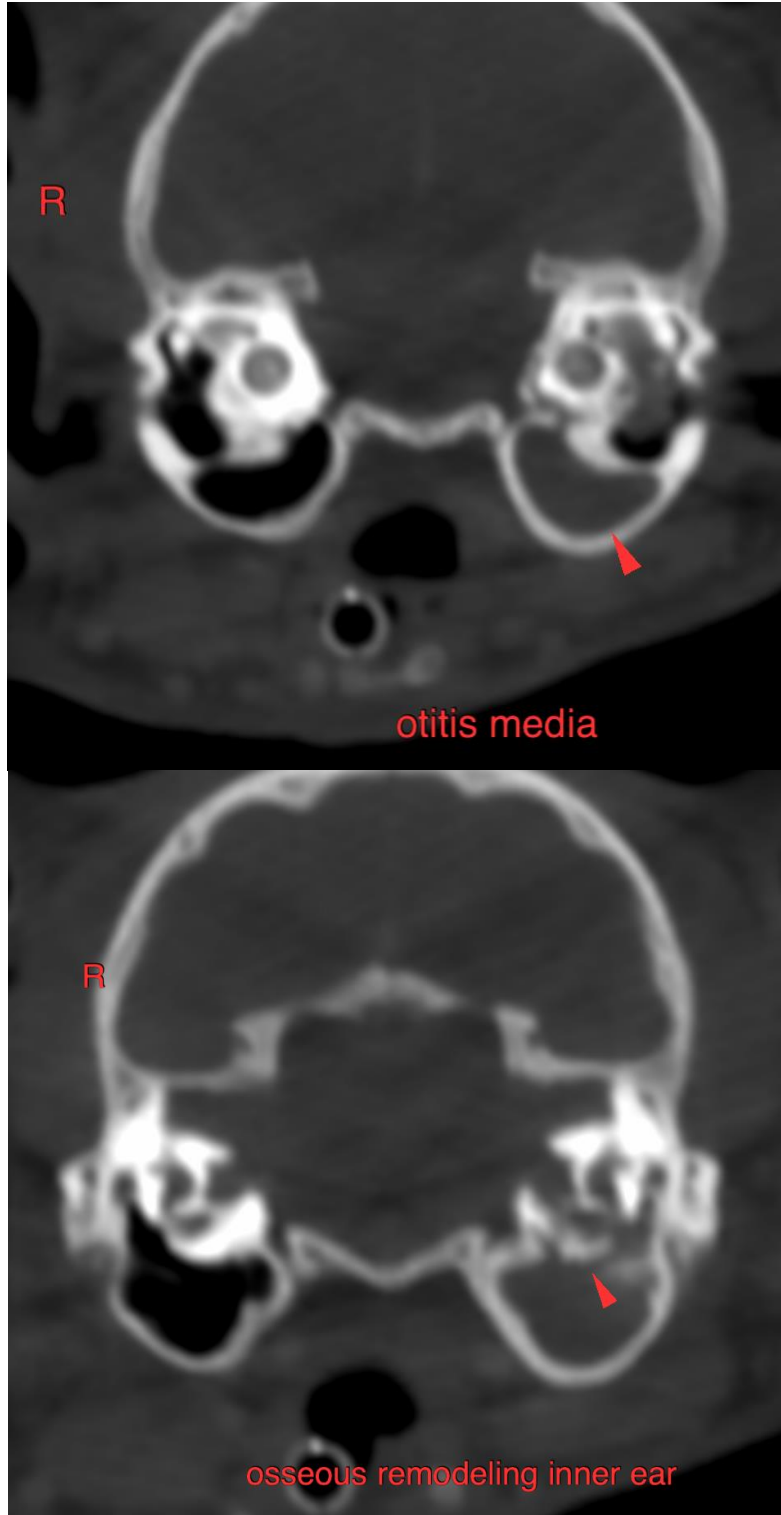
Meaux

**INVOICE**

56150

**DATE**

1-12-23





**PATIENT**

Garth Ru4me Rescue

**SPECIES**

Feline

The information and recommendations provided are based on the images presented by the referring veterinarian/sonographer. No evaluation can be communicated regarding pathology that was not visible in the image/video clips provided.

Thank you for this referral. If the clinical or image interpretation does not parallel your findings or if I can be of any further assistance please contact me.

**BREED**

DSH

**Sebastian Schaub**, Sebastian Schaub, DVM, Dr. med. vet. DipECVDI  
sebast.schaub@gmail.com

**SEX**

Neutered Male

**AGE**

4 Months

**INTERPRETED BY**

Sebastian Schaub, DVM  
Dr. med. vet. DipECVDI

**HOSPITAL NAME**

Mobile Pet Imaging

**REFERRING VET**

Meaux

**INVOICE**

56150

**DATE**

1-12-23