



**PATIENT PRESENTING CLINICAL SIGNS**

**PATIENT** Theo Zenelaj  
**SPECIES** History: Theo is a 14-month-old neutered male English bull dog who has a history of limping on his left hind leg over the last 3 weeks and it seems it is worse recently. On PEX: BAR Not bearing weight on his left hind leg. Negative drawer test on his left and right hind legs. Pain elected upon overextension of his left stifle joint. Patellar luxation on his left leg.

**Canine RADIOGRAPHIC STUDY OF THE PELVIS AND STIFLE JOINTS**

**BREED** A complete set of radiographs of the pelvis and the stifle joints is provided for review.

**English Bulldog RADIOGRAPHIC FINDINGS**

**SEX** Both coxofemoral joints present mild osteophyte new bone formation. The joint space of the coxofemoral joints is mildly incongruent. There is a lateral widening of the subchondral sclerosis of the craniolateral acetabular rim.

**Neutered Male** Both stifle joints present a moderate intracapsular soft tissue swelling, effacing the infrapatellar fat pad and displacing the fascial plane caudally.

**AGE RADIOGRAPHIC DIAGNOSIS**

- 14 Months**
- Moderate articular swelling stifle joints bilaterally, L>R
  - Moderate hip dysplasia

**INTERPRETED BY INTERPRETATION OF THE FINDINGS & FURTHER RECOMMENDATIONS**

**Sebastian Schaub, DVM Dr. med. vet. DipECVDI** As clinically no positive drawer sign is appreciated, and bilateral moderate effusion of the stifle joints is present primary inflammatory origin – such as immune mediated arthritis or infectious causes – needs to be ruled out by a synovial tap. If synovial tap is inconclusive, repeating testing for positive drawer signs or tibial compression test under general anesthesia is recommended.

**HOSPITAL NAME**

Beaches-Fallingbrook  
 VC

**REFERRING VET**

Dr. Sam Sahsavari

**INVOICE**

13403

**DATE**

1/12/22



**PATIENT**

Theo Zenelaj

**SPECIES**

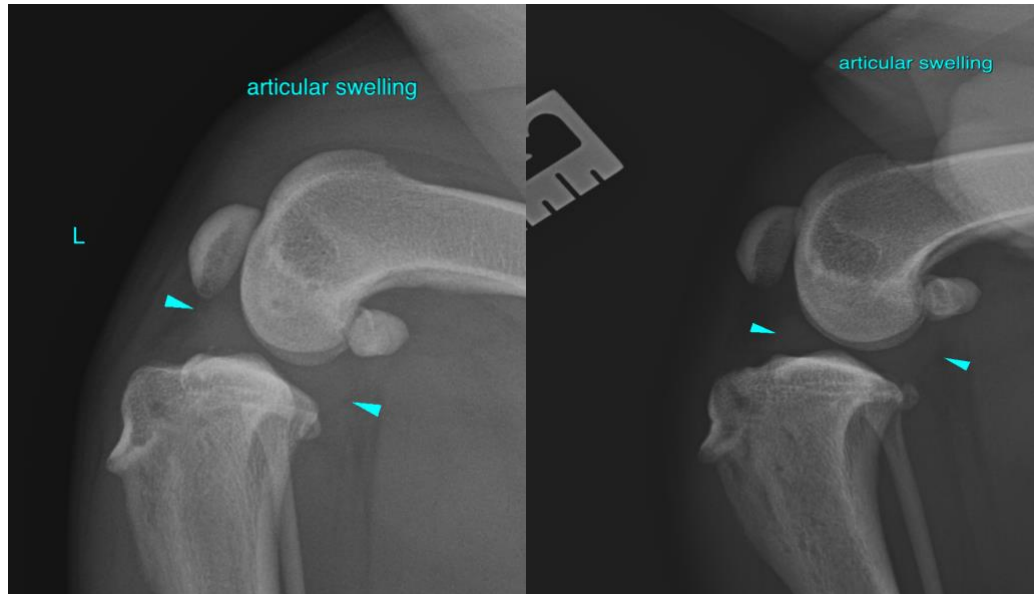
Canine

**BREED**

English Bulldog

**SEX**

Neutered Male



**AGE**

14 Months

**The information and recommendations provided are based on the images presented by the referring veterinarian. No evaluation can be communicated regarding pathology that was not visible in the image/video clips provided.**

Thank you for this referral. If the clinical or image interpretation does not parallel your findings or if I can be of any further assistance please contact me.

**INTERPRETED BY**

Sebastian Schaub,  
DVM Dr. med. vet.  
DipECVDI

**Sebastian Schaub**, Sebastian Schaub, DVM, Dr. med. vet. DipECVDI  
sebast.schaub@gmail.com

**HOSPITAL NAME**

Beaches-Fallingbrook  
VC

**REFERRING VET**

Dr. Sam Sahsavari

**INVOICE**

13403

**DATE**

1/12/22