



PATIENT PRESENTING CLINICAL SIGNS

Sienna Currie History: increased resp rate with abdominal component. increased inspiration effort. whistles in the thorax.

SPECIES Abnormal PE/Chem/CBC/UA Results:

Feline **RADIOGRAPHIC STUDY OF THE THORAX**

Radiographs of the thorax in three imaging planes are provided for review.

BREED RADIOGRAPHIC FINDINGS

Bermese Multifocal mild spondylosis formation is seen along the thoracic spine. Both elbow joints present synovial osteochondromatosis formation.

SEX

Spayed Female The extrathoracic soft tissues present homogeneous without abnormalities.

AGE

16 Years The cardiac silhouette is elongated in the right lateral projection. The pulmonary vasculature is within normal limits. The trachea is normal in diameter and presents the anticipated course. The luminal outline of the trachea is smooth.

INTERPRETED BY

Generalized mild to moderate bronchial pattern is present.

Sebastian Schaub,
DVM Dr. med. vet.
DipECVDI

The lung parenchyma presents the expected architecture and opacity; the intrapulmonary vascular branching is seen up to the third order lung vessels.

HOSPITAL NAME

The diaphragm is well delineated with even surface and the expected mild cranial bulging of the diaphragmatic cupola.

Sylvan Lake VC

The a mineralized body is seen in the imaging plane of the left renal pelvis.

RADIOGRAPHIC DIAGNOSIS

REFERRING VET

Dr. Andrew Hodges

- Bronchial lung pattern
- Mild cardiomegaly without signs of decompensation
- Spondylosis deformans
- Left sided nephrolithiasis

INVOICE

13401

INTERPRETATION OF THE FINDINGS & FURTHER RECOMMENDATIONS

The bronchial lung pattern is suggestive for feline bronchial disease ± bacterial or bronchial superinfection. There are no signs for air-trapping. Consider empirical management.

DATE

1/12/22



PATIENT

The cardiac silhouette is prominent. To rule out cardiomyopathy, a cardiac echo might be considered as advanced diagnostic tool.

Sienna Currie

SPECIES

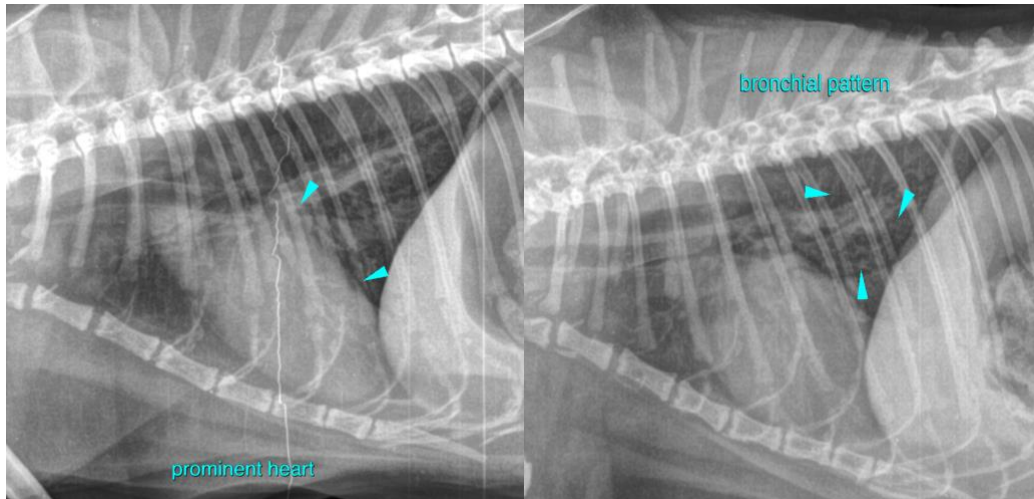
Feline

BREED

Bermese

SEX

Spayed Female



AGE

16 Years

The information and recommendations provided are based on the images presented by the referring veterinarian. No evaluation can be communicated regarding pathology that was not visible in the image/video clips provided.

Thank you for this referral. If the clinical or image interpretation does not parallel your findings or if I can be of any further assistance please contact me.

INTERPRETED BY

Sebastian Schaub,
DVM Dr. med. vet.
DipECVDI

Sebastian Schaub, Sebastian Schaub, DVM, Dr. med. vet. DipECVDI
sebast.schaub@gmail.com

HOSPITAL NAME

Sylvan Lake VC

REFERRING VET

Dr. Andrew Hodges

INVOICE

13401

DATE

1/12/22