



PATIENT PRESENTING CLINICAL SIGNS

Rocket Kemper
SPECIES Canine
BREED Terrier Mix
SEX SF
AGE 13 Years
INTERPRETED BY Sebastian Schaub, DVM
 Dr. med. vet. DipECVDI
HOSPITAL NAME VetMed Consultants
REFERRING VET Alexander Park

Rocket presented with a 3-4 month history of cough/gag. Labored breathing was reported at the beginning of her signs. Radiographs were taken 8/18/21 and pneumonia was diagnosed in left lung. Rocket was hospitalized for a day with oxygen and treated with 2 weeks of Clavamox and Baytril. The cough/gag improved but did not completely resolve. Finished medication and symptoms recurred 1 week later. Radiographs taken again and pneumonia was seen in both lungs. Added enalapril to enrofloxacin for 2 weeks. Response while on medication but then 2-3 weeks later symptoms recurred. Radiographs show lungs are clear on 10/12/21 but still coughing/hacking worse. Most recent radiographs 12/13/21 show pneumonia again. Enalapril and enrofloxacin for 4 weeks - just finished 1 week ago. The cough/gag has never resolved but improves when on antibiotics. Previous diagnosis: Pneumonia Coughing/ hacking: Yes, a lot Sneezing/ reverse sneezing: Normal amount Difficulty breathing: She is breathing fine, now. Did have a period of labored breathing in the beginning. Breathing when asleep: Yes Exercise intolerance: Yes Therapies tried and response: enalapril, enrofloxacin, Clavamox - response while on medication. Current medication: None Current symptoms: Mild cough/hack, finished medications recently. General health status: Eating well and drinking fine. No vomiting or diarrhea. Energy levels normal considering her age.

Abnormal PE/Chem/CBC/UA Results: PE: Gurling sounds are present in the trachea. Lung sounds are clear. No heart murmur. Lab: Bloodwork is dated 12/13/21. CBC - PCV = 47.6%, WBC = 14760, neutrophils = 300, lymphocytes = 11320, monocytes = 2710. Platelets = 195,000. Chemistry - normal. Urinalysis not provided. Bronchoscopy Findings: An endotracheal tube is placed and CT is performed prior to bronchoscopy. The endotracheal tube is filled with yellow mucopurulent discharge. The lower respiratory tract is imaged using a 5 mm flexible video bronchoscope under light sedation. The bronchoscope is cleanly passed through the larynx into the trachea. Yellow mucopurulent discharge is present within the lumen of the larynx and cervical trachea. Mucosal lining the larynx and cervical trachea appears friable because is easily bleeds. There are no visible mucosal abnormalities. Tracheal mucosa is smooth and light pink. The dorsal tracheal membrane is broad and tracheal cartilages are mildly oval at the thoracic inlet. There is mild grade I tracheal collapse. The carina and bronchial bifurcations are sharp. Mainstem bronchi are open and clean. There is no evidence of bronchial collapse or discharge. Evidence of a bronchial foreign body is not found. Bronchoalveolar lavage is performed in the right middle, accessory and left caudal lung lobes using a suction trap and a sterile aspiration catheter. Material is prepared for cytology and culture. The larynx is carefully examined under light sedation and IV Dopram. Normal abduction of arytenoid cartilages is observed during inspiration. Laryngopharyngeal structures are normal. The nasopharynx is imaged using the bronchoscope in retroflexion. The nasopharynx appears normal. There is no evidence of nasopharyngeal masses, foreign bodies or discharge.

COMPUTED TOMOGRAPHY OF THE THORAX

INVOICE A high resolution plain CT study of the thorax is provided for review.

49546

COMPUTED TOMOGRAPHIC FINDINGS

DATE 1-12-22

Mild mineralization of multiple intervertebral discs of the thoracic spine are present. The vertebral body of T10 presents with an ill-defined geographic, ovoid shaped osteolytic lesion.

The sternal, cranial mediastinal and tracheobronchial lymph nodes are small elongated with a normal short-to-long-axis-ratio is < 0.5, the attenuation and contrast enhancement pattern is uniform and considered within normal limits.

**PATIENT**

Rocket Kemper

The cardiovascular structures including the pulmonary vasculature are within normal limits.

Level with the endotracheal tube, a moderate amount of foamy soft tissue material is seen.

SPECIES

Canine

The bronchial tree presents with regular branching and tapers uniformly towards the periphery as expected, the bronchial walls are thin and smooth. The bronchus-to-artery ratio is within normal limits.

BREED

Terrier Mix

Level with the 5th right intercostal space, in the caudolateral aspect of the right cranial lung lobe, a well-defined, uniform nodule, measuring 2.7 mm in diameter is visible. The lung parenchyma presents the expected architecture and attenuation behavior.

Small incidental gas pockets are seen within the esophageal lumen, there is no evidence of abnormal dilation.

SEX

SF

COMPUTED TOMOGRAPHIC DIAGNOSIS

- Monostotic semiaggressive osteolytic lesion vertebral body T10
- Solitary pulmonary nodule right cranial lung lobe
- Exudate in trachea
- Multifocal chondroid disc degeneration thoracic spine

AGE

13 Years

INTERPRETED BYSebastian Schaub, DVM
Dr. med. vet. DipECVCI**INTERPRETATION OF THE FINDINGS & FURTHER RECOMMENDATIONS**

The osteolytic lesion of the vertebral body of T10 presents a mild hypoattenuating center and potentials include either fatty bone marrow replacement or aggressive osteolytic lesion such as granuloma (e.g. mycotic) or neoplastic (e.g. plasmocytoma, metastasis).

HOSPITAL NAME

VetMed Consultants

The solitary pulmonary nodule is not differentials include benign lesions such as granuloma, fibrosis, mucus impaction/round pneumonia, bronchogenic cyst or metastasis. Given in combination with the osteolytic lesion of T10, check the abdomen for primary neoplastic disease. Bone biopsy of the vertebra body of T10 might be a consideration. Re-evaluating the patient by CT in 2-3 month can be considered as well.

REFERRING VET

Alexander Park

The clinical relevance of the pulmonary finding is unclear, the increased amount of exudate in the trachea is suggestive for tracheitis, at this point there is no evidence of pneumonia. Complementing workup by bronchoscopy including BAL can be considered as advanced diagnostic tool.

INVOICE

49546

DATE

1-12-22



PATIENT

Rocket Kemper

SPECIES

Canine

BREED

Terrier Mix

SEX

SF

AGE

13 Years

INTERPRETED BY

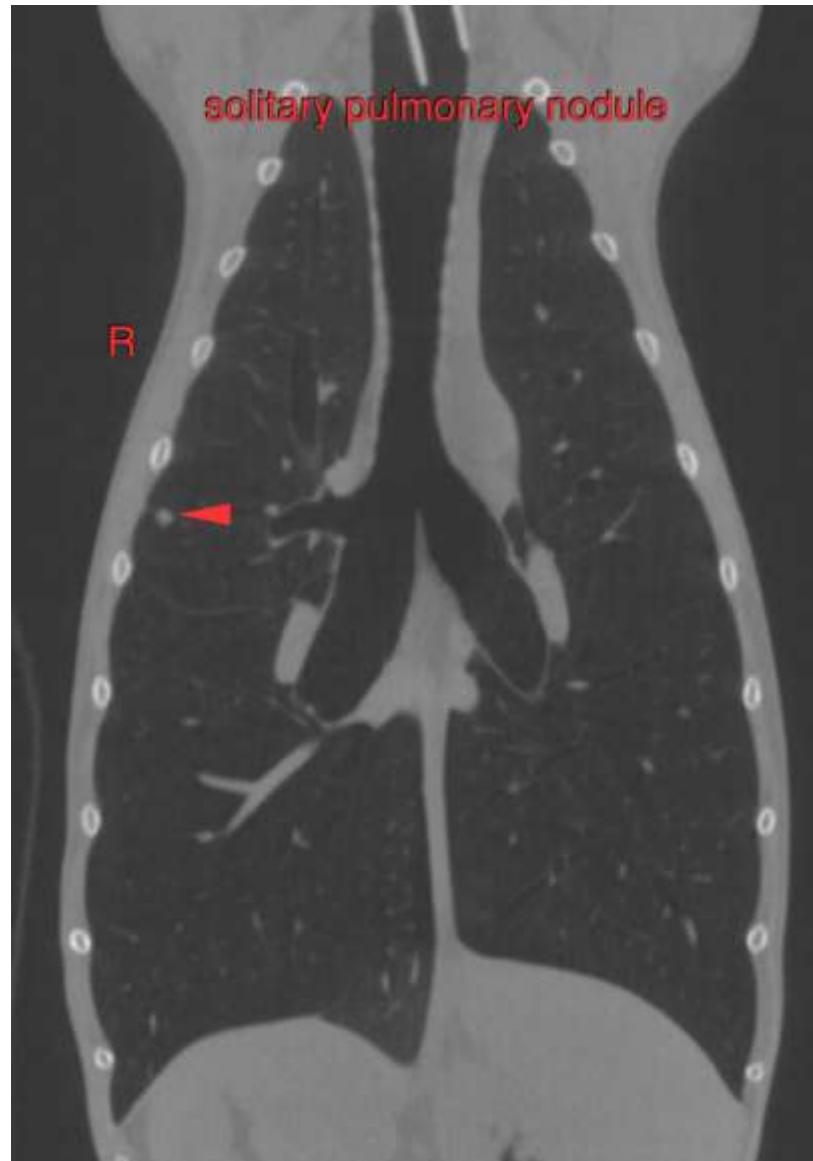
Sebastian Schaub, DVM
Dr. med. vet. DipECVDI

HOSPITAL NAME

VetMed Consultants

REFERRING VET

Alexander Park



INVOICE

49546

DATE

1-12-22



PATIENT

Rocket Kemper

SPECIES

Canine

BREED

Terrier Mix

SEX

SF

AGE

13 Years

INTERPRETED BY

Sebastian Schaub, DVM
Dr. med. vet. DipECVDI

HOSPITAL NAME

VetMed Consultants

REFERRING VET

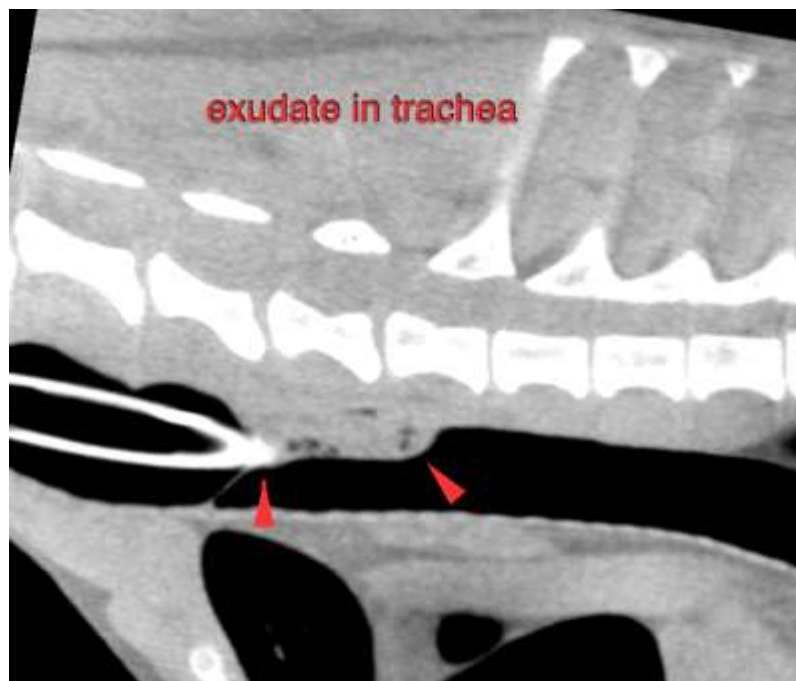
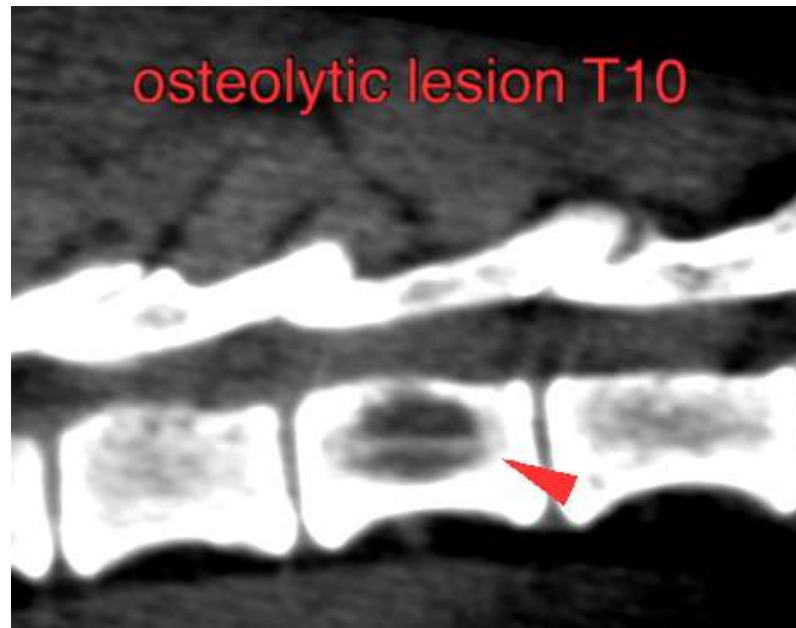
Alexander Park

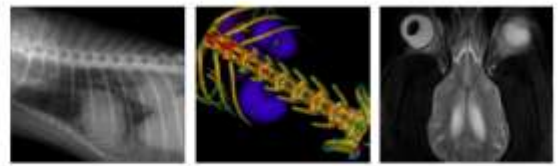
INVOICE

49546

DATE

1-12-22





PATIENT

Rocket Kemper

The information and recommendations provided are based on the images presented by the referring veterinarian. No evaluation can be communicated regarding pathology that was not visible in the image/video clips provided.

SPECIES

Canine

Thank you for this referral. If the clinical or image interpretation does not parallel your findings or if I can be of any further assistance please contact me.

Sebastian Schaub, Sebastian Schaub, DVM, Dr. med. vet. DipECVDI
sebast.schaub@gmail.com

BREED

Terrier Mix

SEX

SF

AGE

13 Years

INTERPRETED BY

Sebastian Schaub, DVM
Dr. med. vet. DipECVDI

HOSPITAL NAME

VetMed Consultants

REFERRING VET

Alexander Park

INVOICE

49546

DATE

1-12-22