



**PATIENT**

Camille Kurtz

**PRESENTING CLINICAL SIGNS**

back pain because jumping and walking gingerly O: BAR, m.m-pink, CRT<2sec, EENT, H/L, Abdo, U/G, skin and coat- Painful on lumbar spine A: back sprain/IVDD

**SPECIES**

Feline

**RADIOGRAPHIC STUDY OF THE THORACIC & LUMBAR SPINE**

A complete set of radiographs of the thoracic & lumbar spine.

**BREED**

Domestic Short Hair

**RADIOGRAPHIC FINDINGS**

The vertebral endplates of the lumbosacral junction present mild spondylosis formation.

**SEX**

Spayed

**RADIOGRAPHIC DIAGNOSIS**

- Mild spondylosis formation L7/S1

**AGE**

12 Years

**INTERPRETATION OF THE FINDINGS & FURTHER RECOMMENDATIONS**

The radiographic study of the thorax presents without specific abnormalities, but mild degenerative changes which might be associated with intervertebral disc protrusion. If clinical signs are refractory to empirical therapy by pain management and rest, cross-sectional imaging can be used as advanced diagnostic tests.

**INTERPRETED BY**

Sebastian Schaub, DVM  
Dr. med. vet. DipECVDI

**HOSPITAL NAME**

Animal Paradise  
Hospital

**REFERRING VET**

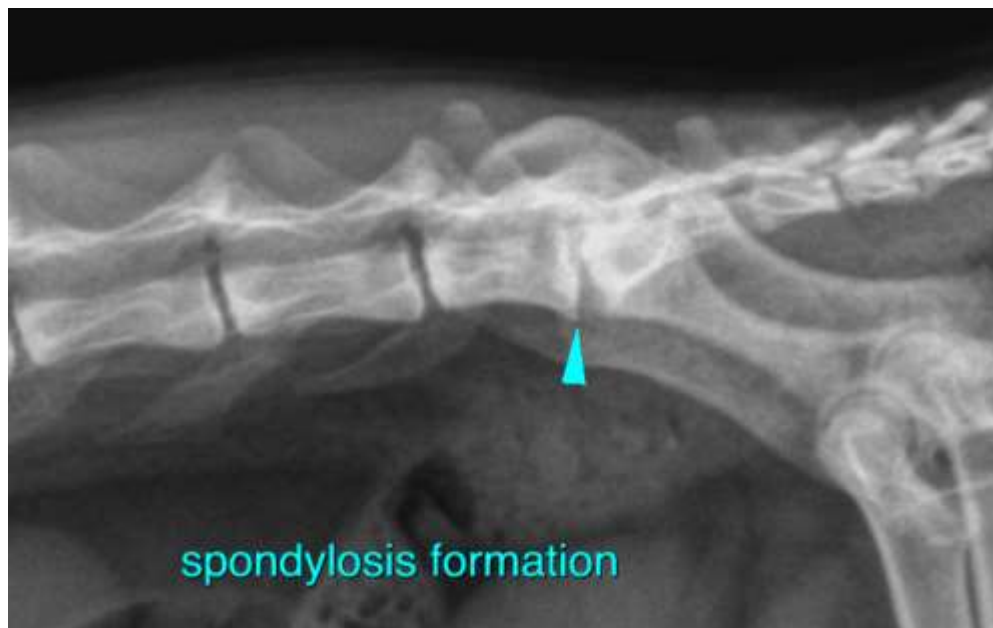
Dr. Mostafa Elshafie

**INVOICE**

49545

**DATE**

1-12-22





**PATIENT**

Camille Kurtz

The information and recommendations provided are based on the images presented by the referring veterinarian. No evaluation can be communicated regarding pathology that was not visible in the image/video clips provided.

**SPECIES**

Feline

Thank you for this referral. If the clinical or image interpretation does not parallel your findings or if I can be of any further assistance please contact me.

**BREED**

Domestic Short Hair

**Sebastian Schaub**, Sebastian Schaub, DVM, Dr. med. vet. DipECVDI  
sebast.schaub@gmail.com

**SEX**

Spayed

**AGE**

12 Years

**INTERPRETED BY**

Sebastian Schaub, DVM  
Dr. med. vet. DipECVDI

**HOSPITAL NAME**

Animal Paradise  
Hospital

**REFERRING VET**

Dr. Mostafa Elshafie

**INVOICE**

49545

**DATE**

1-12-22