



PATIENT

Harley Perrone

SPECIES

Canine

BREED

Boxer Mix

SEX

Spayed Female

AGE

11 Years

WEIGHT

60 pounds

INTERPRETED BY

Sebastian Schaub, DVM
Dr. med. vet. DipECVDI

IMAGING PERFORMED BY

Dr. Mucera

HOSPITAL NAME

Animal Clinic of
Queens

REFERRING VET

Dr. Mucera

INVOICE

13094

DATE

01/11/26

PRESENTING CLINICAL SIGNS

Pt vomiting for a few days. Losing weight. Inappetence.

RADIOGRAPHIC STUDY OF THE THORAX AND ABDOMEN

A complete set of radiographs of the thorax and abdomen is provided for review.

RADIOGRAPHIC FINDINGS

Thorax

The vertebral endplates T4/T5 present mild spondylosis formation.

The extrathoracic soft tissues present homogeneous without abnormalities.

The heart is of normal size and shape; there is no evidence of cardiac chamber or vascular enlargement. The pulmonary vasculature is within normal limits.

The cranial mediastinum presents the expected soft tissue opacity. The mediastinal width is less than twice the width of the vertebral column at the same level.

The trachea is normal in diameter and presents the anticipated course. The luminal outline of the trachea is smooth.

The bronchial tree presents with thin walls and tapers uniformly towards the periphery as expected.

The lung parenchyma presents the expected architecture and opacity; the intrapulmonary vascular branching is seen up to the third order lung vessels.

The diaphragm is well delineated with even surface and the expected mild cranial bulging of the diaphragmatic cupola.

Abdomen

The periarticular bones of both coxofemoral joints present moderate osteophyte new bone formation. The acetabular groove bilaterally is shallow, and the center of the femoral heads is lateral to the dorsal acetabular rim.

No abnormalities of the extra abdominal soft tissues are noted. The abdominal wall is smooth and thin.

The serosal detail is maintained throughout the peritoneal and retroperitoneal space.

The liver is appropriate in position, size and presents uniform opacity.

The splenic head is in the anticipated position and within normal limits for size and opacity. The splenic body and tail are considered normal for position, size, shape and opacity.

Both kidneys are seen and present with normal size, shape, delineation and opacity. The urinary bladder is in its anticipated position. No radiopaque calculi are noted throughout the upper and lower urinary tract.

The stomach is in its anticipated position and is empty but a small amount of gas.

The small intestinal loops are of even diameter and non-dilated, a small amount of gas is seen within the small intestinal loops and considered within normal limits.

The colon is seen in the expected position, moderately distended by gas and presents mild corrugation of the wall.



PATIENT

Harley Perrone

SPECIES

Canine

BREED

Boxer Mix

SEX

Spayed Female

AGE

11 Years

WEIGHT

60 pounds

INTERPRETED BY

Sebastian Schaub, DVM
Dr. med. vet. DipECVDI

IMAGING PERFORMED BY

Dr. Mucera

HOSPITAL NAME

Animal Clinic of
Queens

REFERRING VET

Dr. Mucera

INVOICE

13094

DATE

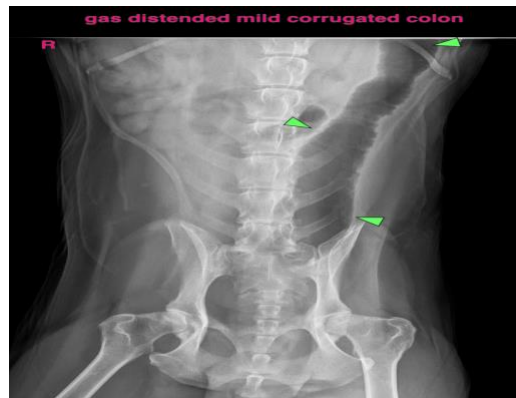
01/11/26

RADIOGRAPHIC DIAGNOSIS

- Overall empty gastrointestinal tract
- Osteoarthritis coxofemoral joints due to hip dysplasia
- Normal thorax

INTERPRETATION OF THE FINDINGS & FURTHER RECOMMENDATIONS

The radiographic study reveals no abnormalities that do explain the vomiting. There is no evidence of radiopaque foreign material, abnormal gas pattern or signs for gastrointestinal mechanical obstruction. The empty colon along with the mild corrugation can be indicative for (gastro)enteritis. Due to the chronic weight loss a complete abdominal ultrasound examination and blood work including cPLI may be beneficial.



The information and recommendations provided are based on the images presented by the referring veterinarian/sonographer. No evaluation can be communicated regarding pathology that was not visible in the image/video clips provided.

Thank you for this referral. If the clinical or image interpretation does not parallel your findings or if I can be of any further assistance please contact me.

Sebastian Schaub, DVM, Dr. med. vet. DipECVDI
info@sonopath.com