



PATIENT

Taco Verfenstein

PRESENTING CLINICAL SIGNS

chronic nasal discharge Left sided

COMPUTED TOMOGRAPHY OF THE SKULL AND THORAX

SPECIES

A high resolution pre- and post-contrast CT study of the skull and thorax is provided for review.

Feline

COMPUTED TOMOGRAPHIC FINDINGS

Skull

BREED

The tooth elements 105, 304 and 404 are absent.

British Shorthair

In the left nasal cavity, advanced destruction of the nasal conchal & turbinate structures is appreciated, resulting in an empty nose. A small amount of fluid attenuating material is attached to the nasal mucosal lining bilaterally.

SEX

Both temporomandibular joints present congruent joint spaces with even subchondral bone surfaces and are considered within normal limits.

MN

Both tympanic bullae are aerated, the mucosal lining is not seen, the bony wall is smooth and thin. The external ear canals are within normal limits.

AGE

11 Months

The brain presents no deviation from normal anatomy and symmetry. The brain parenchyma is homogeneous and within normal limits for attenuation and distribution of contrast enhancement. The ventricular system is non-dilated and symmetric.

INTERPRETED BY

Sebastian Schaub, DVM
Dr. med. vet. DipECVDI

The submandibular and medial retropharyngeal lymph nodes are small and elongated with a normal short-to-long-axis-ratio is < 0.5, the attenuation and contrast enhancement pattern is uniform.

Thorax

HOSPITAL NAME

Animal Surgical
Center

The bony and surrounding soft tissue structures are within normal limits, the growth plates are age related open.

The thymus can be appreciated as multilobulated, mild contrast enhancing structure in the cranial mediastinum.

REFERRING VET

Peace Love Pets

The cardiovascular structures including the pulmonary vasculature are within normal limits.

The bronchial tree presents with regular branching and tapers uniformly towards the periphery as expected, the bronchial walls are thin and smooth. The bronchus-to-artery ratio is within normal limits.

INVOICE

56119

The ventral aspects of the lung parenchyma present zones with ground glass attenuation behavior. The volume of the lung parenchyma is generalized mildly decreased.

Small incidental gas pockets are seen within the esophageal lumen, there is no evidence of abnormal dilation.

DATE

1-11-23

COMPUTED TOMOGRAPHIC DIAGNOSIS

- Destructive rhinitis, L>>>R
- Zones of dystelectasis of the lung parenchyma due to general anesthesia



PATIENT • Absent triada105, 304 and 404

Taco Verfenstein

INTERPRETATION OF THE FINDINGS & FURTHER RECOMMENDATIONS

The findings are consistent with chronic destructive rhinitis, predominantly of the left nasal cavity. The causative agent is most likely primary viral ± bacterial or less likely mycotic superinfection.

SPECIES

Feline

Rhinoscopy with biopsy and samples for microbial culture can be used as advanced diagnostic test.

BREED

British Shorthair

There is no evidence of a nasopharyngeal polyp.

The zones with increased attenuation of the ventral aspects of the lung are most consistent with dystelectasis, pneumonia is a differential, but the odds are lower.

SEX

MN

AGE

11 Months

INTERPRETED BY

Sebastian Schaub, DVM
Dr. med. vet. DipECVDI

HOSPITAL NAME

Animal Surgical
Center

REFERRING VET

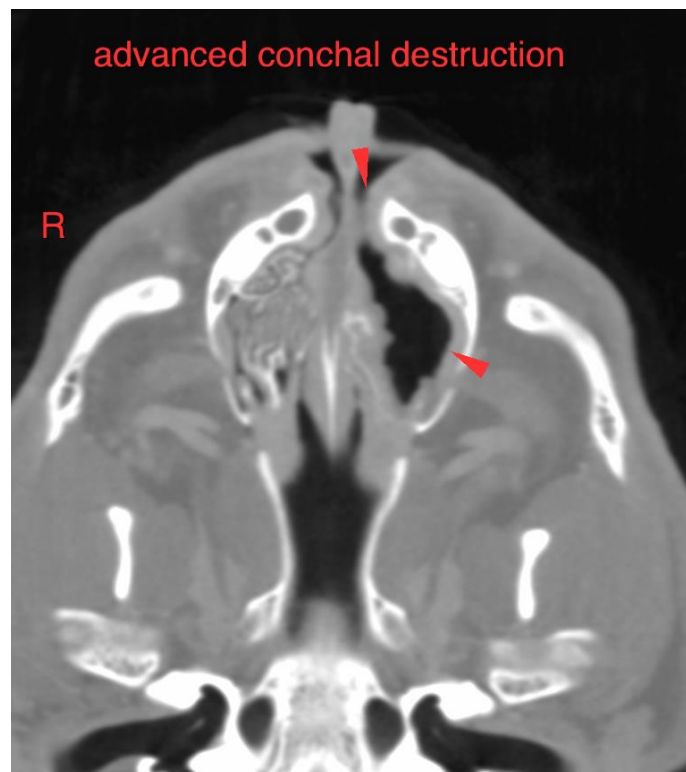
Peace Love Pets

INVOICE

56119

DATE

1-11-23





PATIENT

Taco Verfenstein

SPECIES

Feline

BREED

British Shorthair

SEX

MN

AGE

11 Months

INTERPRETED BY

Sebastian Schaub, DVM
Dr. med. vet. DipECVDI

HOSPITAL NAME

Animal Surgical
Center

REFERRING VET

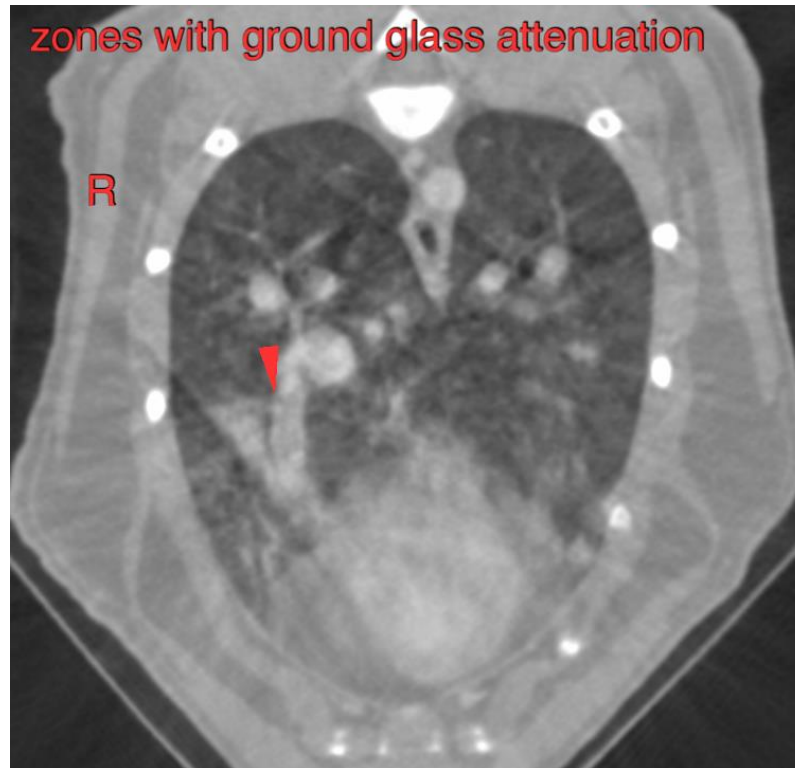Peace Love Pets

INVOICE

56119

DATE

1-11-23



The information and recommendations provided are based on the images presented by the referring veterinarian/sonographer. No evaluation can be communicated regarding pathology that was not visible in the image/video clips provided.

Thank you for this referral. If the clinical or image interpretation does not parallel your findings or if I can be of any further assistance please contact me.

Sebastian Schaub, Sebastian Schaub, DVM, Dr. med. vet. DipECVDI
sebast.schaub@gmail.com