

**PATIENT**

Truman Kanter

PRESENTING CLINICAL SIGNS

dental/extraction planning

SPECIES

Canine

COMPUTED TOMOGRAPHY OF THE SKULL

A high resolution plain CT study of the viscerocranium is provided for review.

BREED

Schnauzer

COMPUTED TOMOGRAPHIC FINDINGS

The dentition is complete. The mesial palatine root of triadan 208 presents a moderately widening of the periodontal space. A generalized moderate horizontal bone loss is seen level with the upper and lower incisor teeth

SEX

MN

The nasal cavity presents the expected aerated spaces between thin & even conchae and turbinates with smooth mucosal lining.

Both temporomandibular joints present congruent joint spaces with even subchondral bone surfaces and are considered within normal limits.

AGE

4

COMPUTED TOMOGRAPHIC DIAGNOSIS

- Advanced periodontal disease triadan 208
- Generalized horizontal bone loss level with the upper & lower incisor teeth – most accentuated in the mandibular incisors

INTERPRETED BY

Sebastian Schaub, DVM
Dr. med. vet. DipECVDI

INTERPRETATION OF THE FINDINGS & FURTHER RECOMMENDATIONS

A complete dental workup has already been scheduled. Extraction of triadan 208 appears beneficial.

HOSPITAL NAME

Advanced Animal
Imaging

REFERRING VET

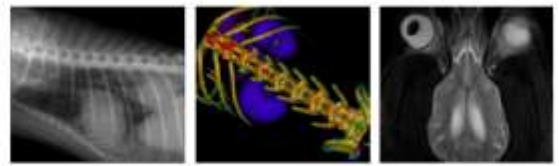
Blair Hollowell, DVM

INVOICE

49485

DATE

1-11-22



PATIENT

Truman Kanter

SPECIES

Canine

BREED

Schnauzer

SEX

MN

AGE

4

INTERPRETED BY

Sebastian Schaub, DVM
Dr. med. vet. DipECVDI

HOSPITAL NAME

Advanced Animal
Imaging

REFERRING VET

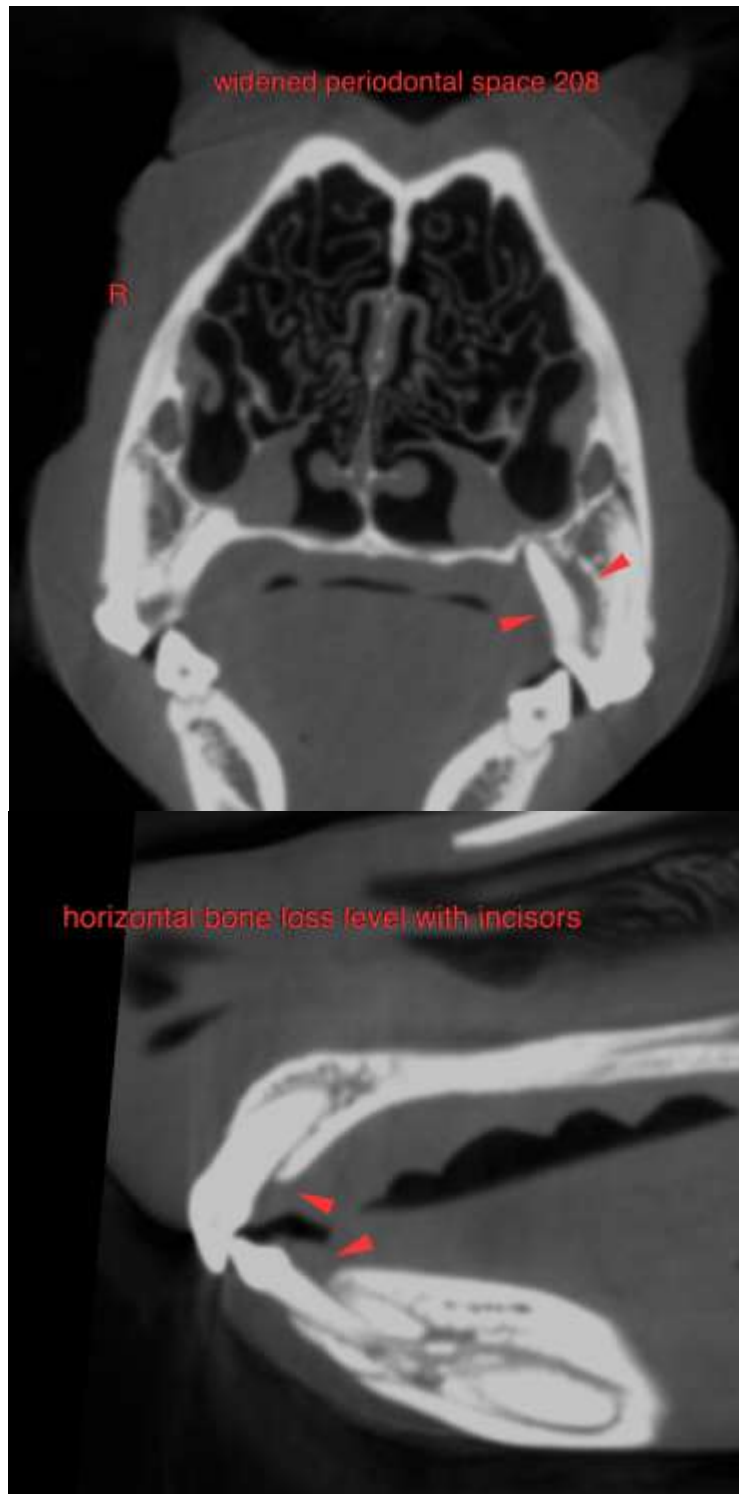Blair Hollowell, DVM

INVOICE

49485

DATE

1-11-22





PATIENT

Truman Kanter

The information and recommendations provided are based on the images presented by the referring veterinarian. No evaluation can be communicated regarding pathology that was not visible in the image/video clips provided.

SPECIES

Canine

Thank you for this referral. If the clinical or image interpretation does not parallel your findings or if I can be of any further assistance please contact me.

BREED

Schnauzer

Sebastian Schaub, Sebastian Schaub, DVM, Dr. med. vet. DipECVDI
sebast.schaub@gmail.com

SEX

MN

AGE

4

INTERPRETED BY

Sebastian Schaub, DVM
Dr. med. vet. DipECVDI

HOSPITAL NAME

Advanced Animal
Imaging

REFERRING VET

Blair Hollowell, DVM

INVOICE

49485

DATE

1-11-22