



PATIENT PRESENTING CLINICAL SIGNS

Loki Cool Vomited 3 times yesterday. Vomiting clear fluid and having clear diarrhea. Lethargic. Indoor only. No vaccine history.

SPECIES RADIOGRAPHIC STUDY OF THE ABDOMEN

Feline Radiographs of the abdomen in three imaging planes are provided for review.

RADIOGRAPHIC FINDINGS

BREED

DSH

The surrounding bony structures are within normal limits.

No abnormalities of the extraabdominal soft tissues are noted. The abdominal wall is smooth and thin.

SEX

FS

The serosal detail is maintained throughout the peritoneal and retroperitoneal space.

The liver is appropriate in position, size and presents uniform opacity.

AGE

8 Months

The splenic head is in the anticipated position and within normal limits for size and opacity. Medial to the spleen, a mild patchy soft tissue opacity of the peritoneal fat is seen.

INTERPRETED BY

Sebastian Schaub, DVM
Dr. med. vet. DipECVDI

Both kidneys are seen and present with normal size, shape, delineation and opacity. The urinary bladder is in its anticipated position. No radiopaque calculi are noted throughout the upper and lower urinary tract.

The stomach is in its anticipated position and is empty.

HOSPITAL NAME

Elizabeth Animal
Hospital

The small intestinal loops are of even diameter and non-dilated, a small amount of gas is seen within the small intestinal loops and considered within normal limits.

The colon is seen in the expected position and is moderately distended by homogeneous soft tissue opaque material with interspersed gas bubbles. Two ovoid shaped faint soft tissue opacities are seen dorsal to the descending colon, level with L5/L6.

REFERRING VET

Sareena Enloe, DVM

RADIOGRAPHIC DIAGNOSIS

- Possible focal peritonitis medial aspect of spleen
- Fluid filled colon
- Empty stomach
- Suspect lymphadenopathy colonic lymph nodes

INVOICE

49488

INTERPRETATION OF THE FINDINGS & FURTHER RECOMMENDATIONS

DATE

1-11-22

The pattern of the gastrointestinal tract is suggestive for underlying gastroenteritis. There is no evidence of radiopaque foreign material or signs for gastrointestinal mechanical obstruction. The focal patchy soft tissue opacification of the peritoneal fat medial to the spleen, can be secondary to underlying pancreatitis – a potential source for the current clinical signs as well. If not done so yet, considered complete blood work including fpl.



PATIENT

Loki Cool

If clinical signs are refractory to therapy, recommend follow up radiographs or a complete abdominal ultrasound examination.

SPECIES

Feline

BREED

DSH

SEX

FS

AGE

8 Months

INTERPRETED BY

Sebastian Schaub, DVM
Dr. med. vet. DipECVDI

HOSPITAL NAME

Elizabeth Animal
Hospital

REFERRING VET

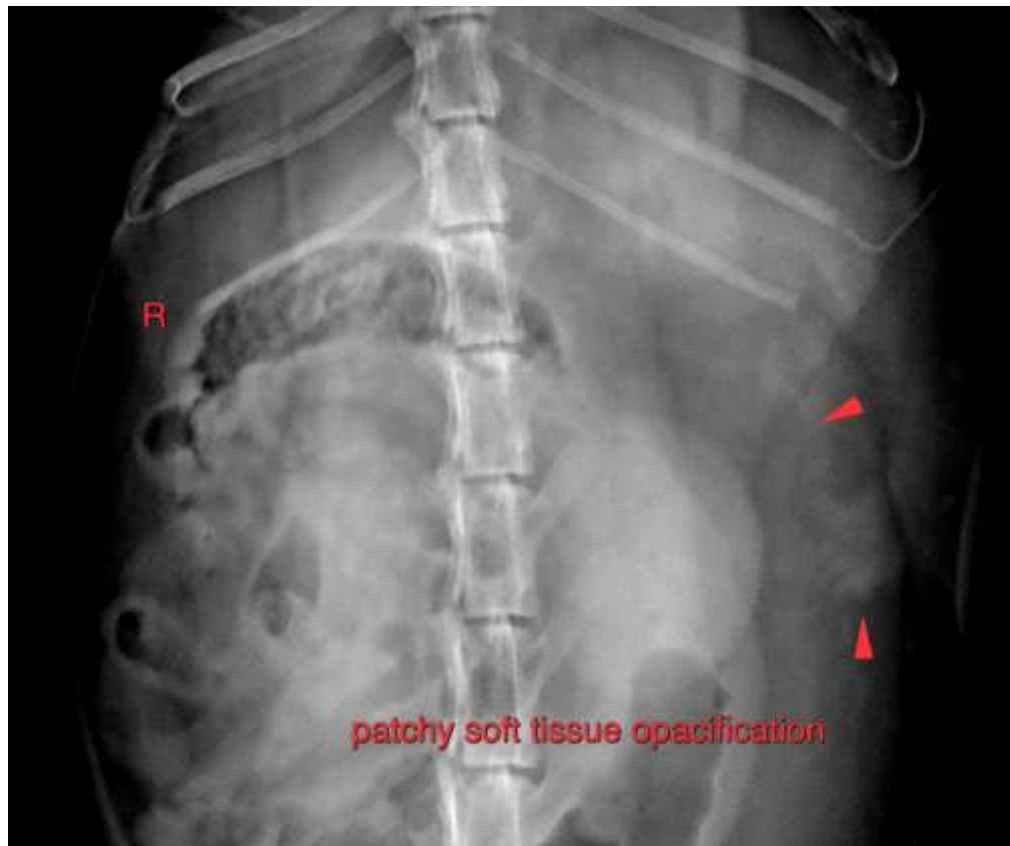
Sareena Enloe, DVM

INVOICE

49488

DATE

1-11-22





PATIENT

Loki Cool

SPECIES

Feline

BREED

DSH

SEX

FS

AGE

8 Months

INTERPRETED BY

Sebastian Schaub, DVM
Dr. med. vet. DipECVDI

HOSPITAL NAME

Elizabeth Animal
Hospital

REFERRING VET

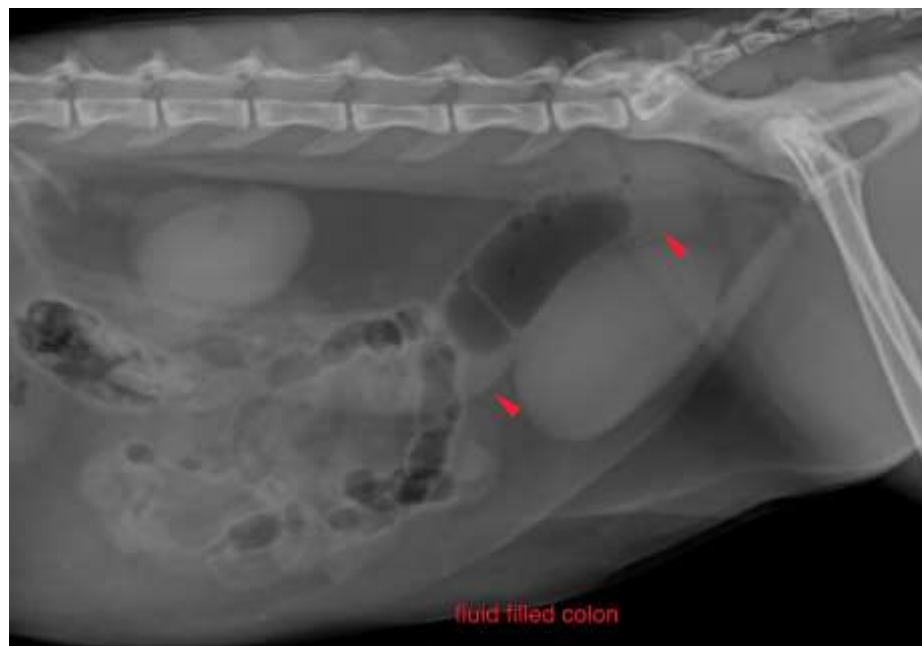
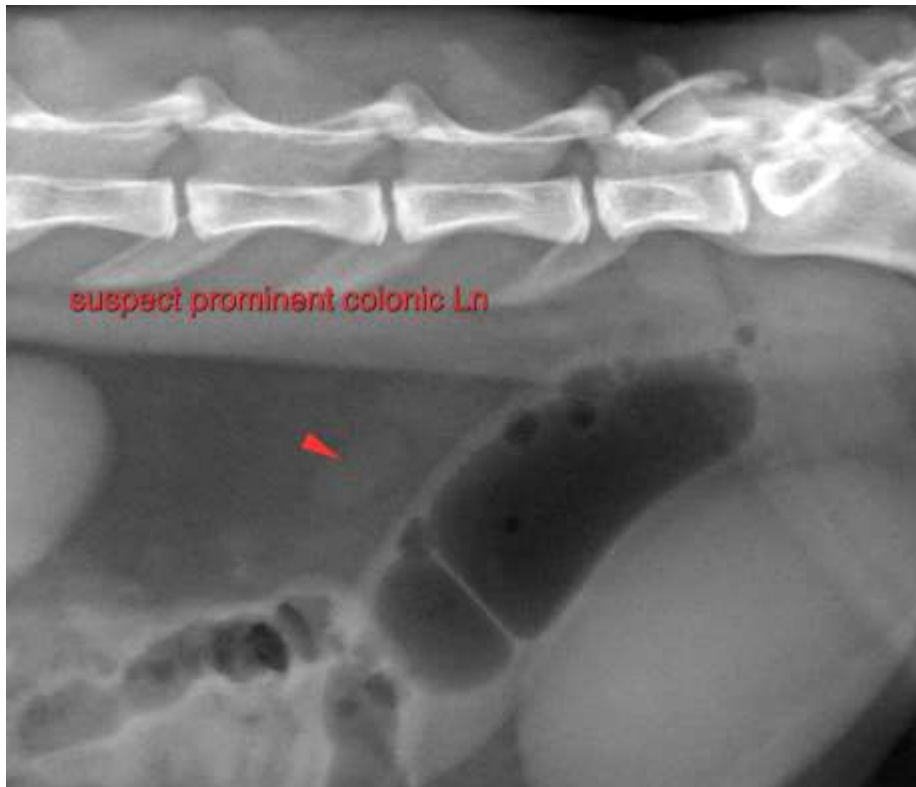
Sareena Enloe, DVM

INVOICE

49488

DATE

1-11-22





PATIENT

Loki Cool

The information and recommendations provided are based on the images presented by the referring veterinarian. No evaluation can be communicated regarding pathology that was not visible in the image/video clips provided.

SPECIES

Feline

Thank you for this referral. If the clinical or image interpretation does not parallel your findings or if I can be of any further assistance please contact me.

BREED

DSH

Sebastian Schaub, Sebastian Schaub, DVM, Dr. med. vet. DipECVDI
sebast.schaub@gmail.com

SEX

FS

AGE

8 Months

INTERPRETED BY

Sebastian Schaub, DVM
Dr. med. vet. DipECVDI

HOSPITAL NAME

Elizabeth Animal
Hospital

REFERRING VET

Sareena Enloe, DVM

INVOICE

49488

DATE

1-11-22