

**PATIENT**

Joker Essman

PRESENTING CLINICAL SIGNS

Coughing, sputum with blood

SPECIES

Canine

RADIOGRAPHIC STUDY OF THE THORAX

A right lateral projection of the thorax is provided for review.

BREED

Puggle Mix

RADIOGRAPHIC FINDINGS

The vertebral endplates T5/T6 present moderate spondylosis formation.

The extrathoracic soft tissues present homogeneous without abnormalities.

The heart is of normal size and shape, there is no evidence of cardiac chamber or vascular enlargement. The pulmonary vasculature is within normal limits.

SEX

Male Neutered

The cranial mediastinum presents the expected soft tissue opacity. The mediastinal width is less than twice the width of the vertebral column at the same level.

AGE

6 Years

The trachea is normal in diameter and presents the anticipated course. The luminal outline of the trachea is smooth.

INTERPRETED BYSebastian Schaub, DVM
Dr. med. vet. DipECVDI

The bronchial tree presents with thin walls and tapers uniformly towards the periphery as expected.

Level with T8/T9, the lung parenchyma presents a local ill-defined mild to moderate ground glass opacification. The remainder of the lung parenchyma present the expected architecture and opacity; the intrapulmonary vascular branching is seen up to the third order lung vessels.

HOSPITAL NAMENew Bridge
Veterinary Practice

The diaphragm is well delineated with even surface and the expected mild cranial bulging of the diaphragmatic cupola.

RADIOGRAPHIC DIAGNOSIS

- Possible localized unstructured interstitial lung pattern caudodorsal lung field
- Spondylosis deformans

REFERRING VET

Dr. Abina Glennon

INTERPRETATION OF THE FINDINGS & FURTHER RECOMMENDATIONS

The localized unstructured interstitial pattern can be caused by zone of pneumonitis, non-cardiogenic pulmonary edema, interstitial hemorrhage or neoplastic disease. Consider complementing the current radiographic study but at least a second imaging plane (VD ± left lateral), to rule out pathology which might be effaced in the right lateral view.

INVOICE

49477

DATE

1-11-22



PATIENT

Joker Essman

SPECIES

Canine

BREED

Puggle Mix

SEX

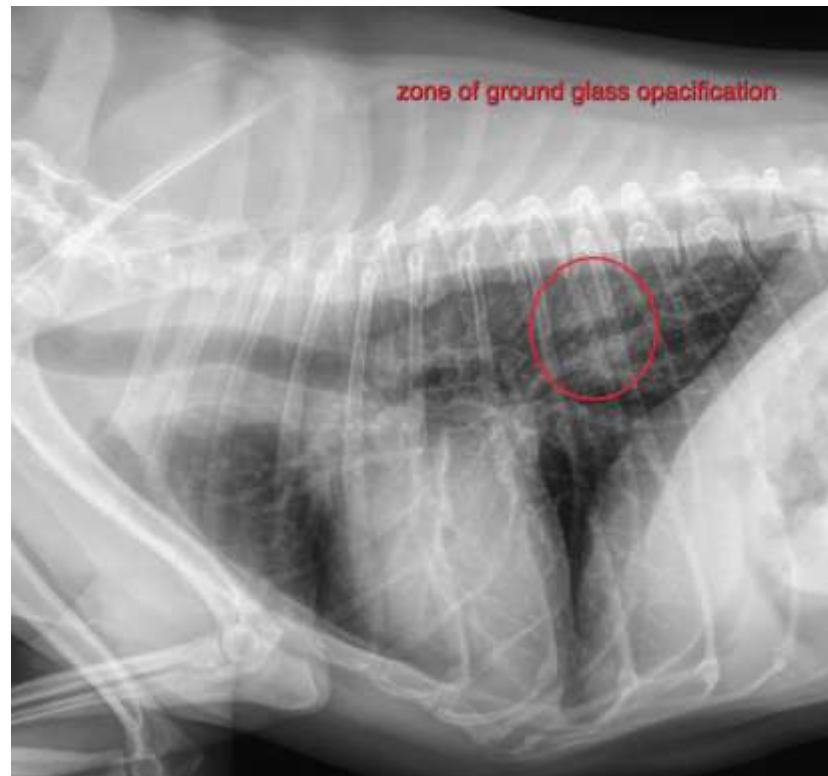
Male Neutered

AGE

6 Years

INTERPRETED BY

Sebastian Schaub, DVM
Dr. med. vet. DipECVDI



HOSPITAL NAME

New Bridge
Veterinary Practice

REFERRING VET

Dr. Abina Glennon

INVOICE

49477

DATE

1-11-22

The information and recommendations provided are based on the images presented by the referring veterinarian. No evaluation can be communicated regarding pathology that was not visible in the image/video clips provided.

Thank you for this referral. If the clinical or image interpretation does not parallel your findings or if I can be of any further assistance please contact me.

Sebastian Schaub, Sebastian Schaub, DVM, Dr. med. vet. DipECVDI
sebast.schaub@gmail.com