



PATIENT PRESENTING CLINICAL SIGNS

Luna Lamoureux Two week history of left-sided vestibular signs, left facial nerve paralysis and Horner's. Non-responsive to 1 week of treatment with clavaseptin. Upper respiratory noise.

SPECIES COMPUTED TOMOGRAPHY OF THE SKULL

Feline A high resolution pre- and post-contrast CT study of the skull is provided for review.

COMPUTED TOMOGRAPHIC FINDINGS

BREED Triadan 109 & 209 present evidence of resorptive lesions.

DSH The nasal cavity presents the expected aerated spaces between thin & even conchae and turbinates with smooth mucosal lining.

SEX Both temporomandibular joints present congruent joint spaces with even subchondral bone surfaces and are considered within normal limits.

FS The left tympanic bulla is filled with soft tissue attenuating material and presents an increased volume. The wall of the left tympanic bulla presents multifocal lytic lesions with multifocal perforation of the wall of the left tympanic bulla. An ill-defined soft tissue swelling of the retropharyngeal tissue is seen, surrounding the left tympanic bulla with granular mineralization of the soft tissues in the caudal aspect. The nasopharynx is distorted by the mass effect. Advanced osteolysis of the tympanic part of the left temporal bone, perforating the cranial fossa is appreciated; extending up into the base of the right condyle of the occipital bone.

AGE

6 Years

INTERPRETED BY

Sebastian Schaub, DVM
Dr. med. vet. DipECVDI

The right tympanic bulla contains a moderate amount of soft tissue material and the wall of the right tympanic bulla is thickened and presents multiple osteolytic lesions. The external ear canals are within normal limits.

The external ear canals present no abnormalities.

HOSPITAL NAME

Animal Health
Partners

The brain presents no deviation from normal anatomy and symmetry. The brain parenchyma is homogeneous and within normal limits for attenuation. The ventricular system is non-dilated and symmetric.

The left medial retropharyngeal lymph node is prominent.

REFERRING VET

Dr. Steph Lovell

COMPUTED TOMOGRAPHIC DIAGNOSIS

- Left sided advanced chronic otitis media with chronic remodeling of the osseous structures, perforation of the cranial fossa and surrounding retropharyngeal soft tissue swelling and mass effect on the nasopharynx
- Right sided chronic otitis media
- Lymphadenopathy left medial retropharyngeal lymph node

INVOICE

56097

INTERPRETATION OF THE FINDINGS & FURTHER RECOMMENDATIONS

DATE

1-10-23

The chronic left sided otitis media with extensive osteomyelitis is a plausible explanation for the presenting clinical signs and the surrounding likely inflammatory retropharyngeal swelling with mass effect on the nasopharynx is explaining the respiratory clinical signs. Theoretically neoplastic disease is a potential, but the location would be unusual. Suspect secondary reactive hyperplasia of the left medial retropharyngeal lymph node. Surgical management of the left sided ventral bulla osteotomy is considered as the therapy of choice, prior to surgical intervention, FNA



PATIENT

sampling of the swelling can be used to rule out signs for potential malignant cells.

Luna Lamoureux

SPECIES

Feline

BREED

DSH

SEX

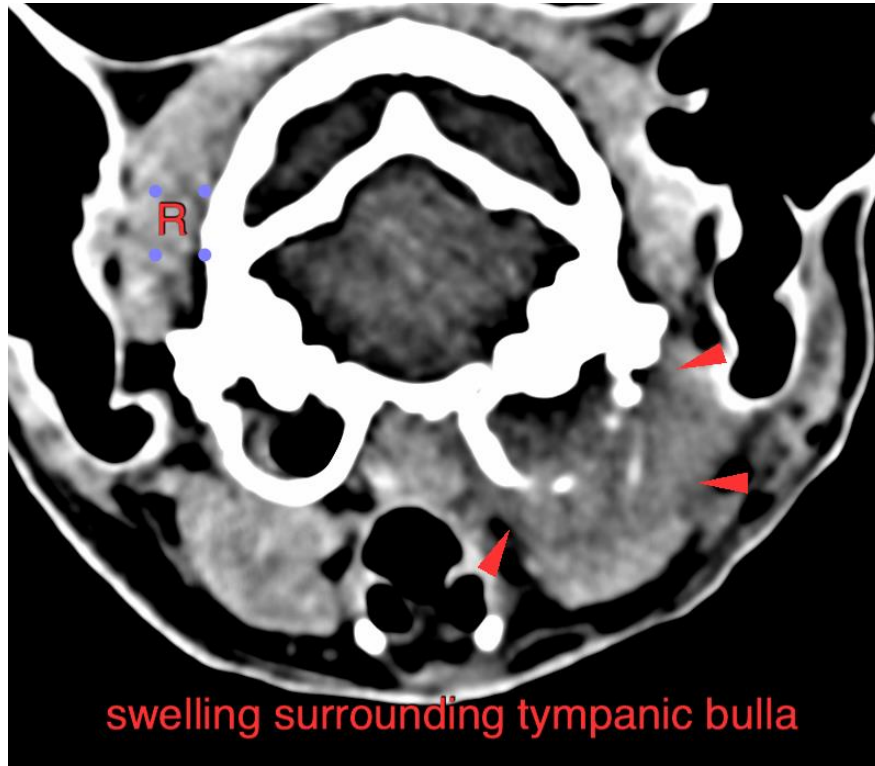
FS

AGE

6 Years

INTERPRETED BY

Sebastian Schaub, DVM
Dr. med. vet. DipECVDI



HOSPITAL NAME

Animal Health
Partners

REFERRING VET

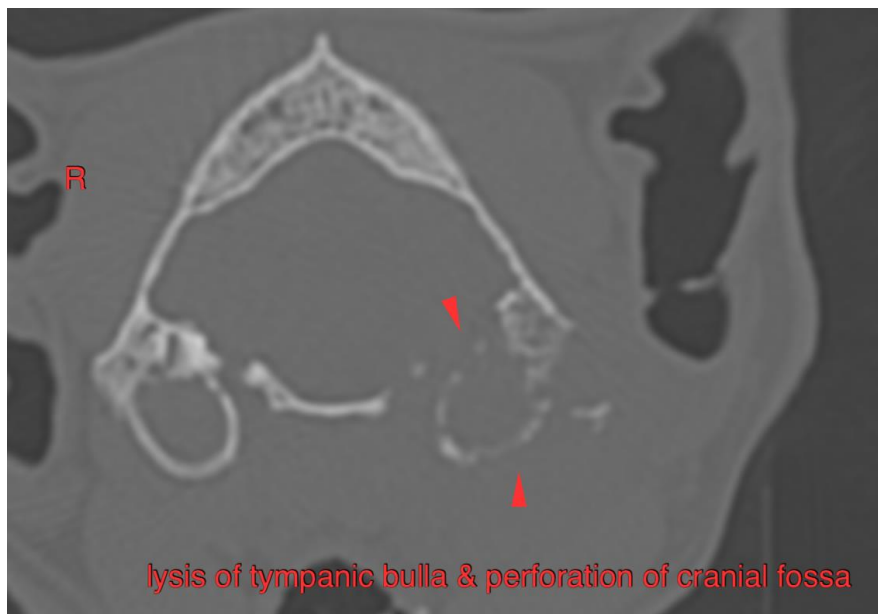
Dr. Steph Lovell

INVOICE

56097

DATE

1-10-23





PATIENT

Luna Lamoureux

The information and recommendations provided are based on the images presented by the referring veterinarian/sonographer. No evaluation can be communicated regarding pathology that was not visible in the image/video clips provided.

SPECIES

Feline

Thank you for this referral. If the clinical or image interpretation does not parallel your findings or if I can be of any further assistance please contact me.

BREED

DSH

Sebastian Schaub, Sebastian Schaub, DVM, Dr. med. vet. DipECVDI
sebast.schaub@gmail.com

SEX

FS

AGE

6 Years

INTERPRETED BY

Sebastian Schaub, DVM
Dr. med. vet. DipECVDI

HOSPITAL NAME

Animal Health
Partners

REFERRING VET

Dr. Steph Lovell

INVOICE

56097

DATE

1-10-23