

**PATIENT**

Walter Pelton

PRESENTING CLINICAL SIGNS

Hx cervical pain november 2021 resolved with rest and pain management, acute lumbar pain last week

SPECIES

Canine

RADIOGRAPHIC STUDY OF THE CERVICAL, THORACIC AND LUMBAR SPINE

Radiographs of the entire spine in orthogonal imaging planes are provided for review.

BREED

Standard Poodle

RADIOGRAPHIC FINDINGS

The osseous and surrounding soft tissue structures of the cervical spine are within normal limits. The subchondral bone of the vertebral endplates is smooth.

SEX

MN

The intervertebral disc space T11/T12 is mildly narrowed. Physiological narrowing of the intervertebral disc space T10/T11 is present (anticlinal vertebra).

The remainder of the thoracic spine are unremarkable.

AGE

2.8 Years

The lumbar spine presents without pathological findings and the surrounding soft tissue structures are within normal limits.

RADIOGRAPHIC DIAGNOSIS

- Possible discopathy T11/T12
- Normal cervical & lumbar spine

INTERPRETED BY

Sebastian Schaub, DVM
Dr. med. vet. DipECVDI

INTERPRETATION OF THE FINDINGS & FURTHER RECOMMENDATIONS

The mildly narrowed intervertebral disc space T11/T12 can be a sequela to discopathy or is artefactual due to oblique projection of the respective intervertebral disc space. If clinical signs are refractory to empirical therapy or neurological deficits develop, complementing workup by a CT study of the spine is considered beneficial.

HOSPITAL NAME

Boca Park Animal
Hospital

REFERRING VET

Laura Warren

INVOICE

49435

DATE

1-10-22



PATIENT

Walter Pelton

SPECIES

Canine

BREED

Standard Poodle

SEX

MN

AGE

2.8 Years

INTERPRETED BY

Sebastian Schaub, DVM
Dr. med. vet. DipECVDI

HOSPITAL NAME

Boca Park Animal
Hospital

REFERRING VET

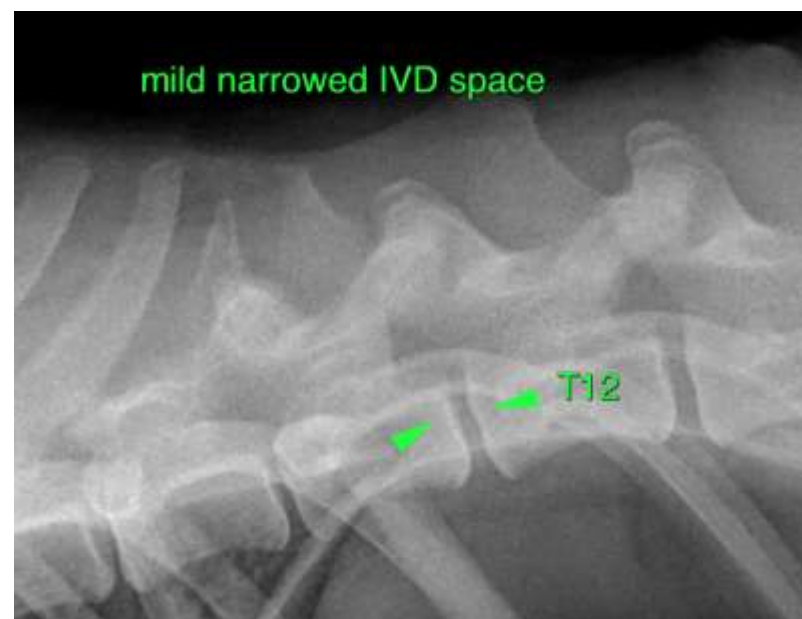
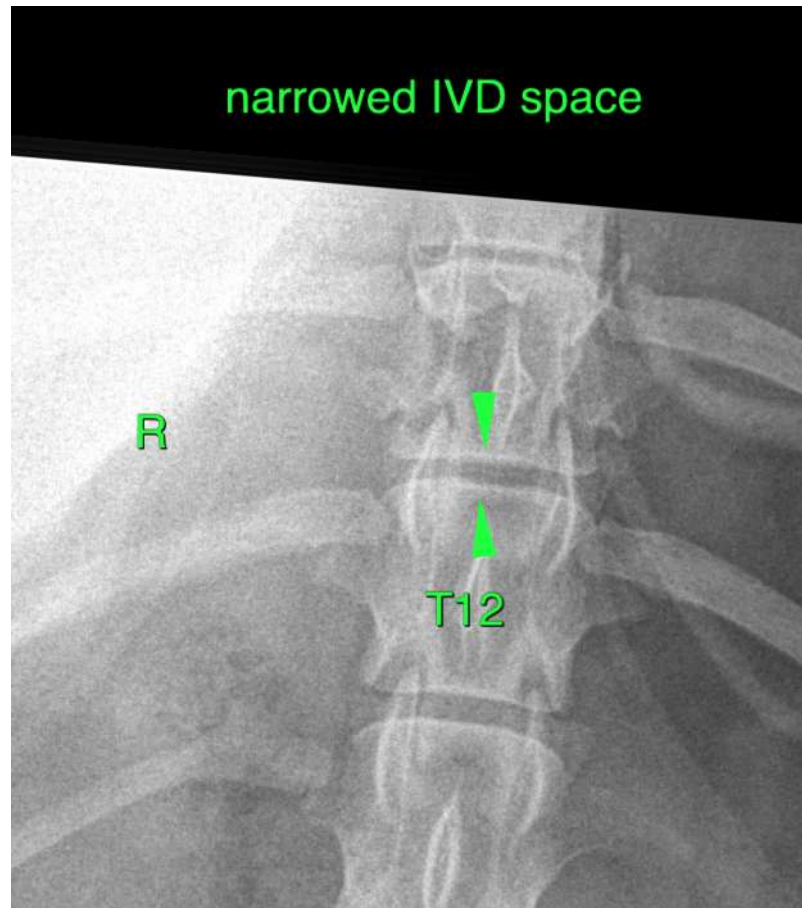
Laura Warren

INVOICE

49435

DATE

1-10-22





PATIENT

Walter Pelton

SPECIES

Canine

The information and recommendations provided are based on the images presented by the referring veterinarian. No evaluation can be communicated regarding pathology that was not visible in the image/video clips provided.

BREED

Standard Poodle

Thank you for this referral. If the clinical or image interpretation does not parallel your findings or if I can be of any further assistance please contact me.

Sebastian Schaub, Sebastian Schaub, DVM, Dr. med. vet. DipECVDI
sebast.schaub@gmail.com

SEX

MN

AGE

2.8 Years

INTERPRETED BY

Sebastian Schaub, DVM
Dr. med. vet. DipECVDI

HOSPITAL NAME

Boca Park Animal
Hospital

REFERRING VET

Laura Warren

INVOICE

49435

DATE

1-10-22