



PATIENT

Cecil NYC Teens for Animals

PRESENTING CLINICAL SIGNS

Cecil presented for back issues limb lameness of 1 month duration . On exam pain on palpation of thoracolumbar region.

SPECIES

Feline

COMPUTED TOMOGRAPHY OF THE THORACIC & LUMBAR SPINE

A high resolution myelographic CT study of the thoracic & lumbar spine is provided for review.

BREED

DSH

COMPUTED TOMOGRAPHIC FINDINGS

The osseous and surrounding soft tissue structures of the thoracic & lumbar spine are within normal limits.

SEX

Female Spayed

The subarachnoidal space presents an even diameter throughout and the spinal cord presents with the expected diameter. A small gas bubbles is seen in the dorsal aspect of the subarachnoidal space level L4/L5.

COMPUTED TOMOGRAPHIC DIAGNOSIS

- Normal thoracic & lumbar spine

AGE

7 Months

INTERPRETATION OF THE FINDINGS & FURTHER RECOMMENDATIONS

The CT study of the thoracic & lumbar spine is negative for pathology. There are no signs for compressive myelopathy or malformation along the thoracic/lumbar spine. In case of strong clinical suspicion for intramedullary pathology along the thoracic/lumbar spine, consider complementing workup by an MRI study.

INTERPRETED BY

Sebastian Schaub, DVM
Dr. med. vet. DipECVDI

HOSPITAL NAME

Animal Surgical Center

REFERRING VET

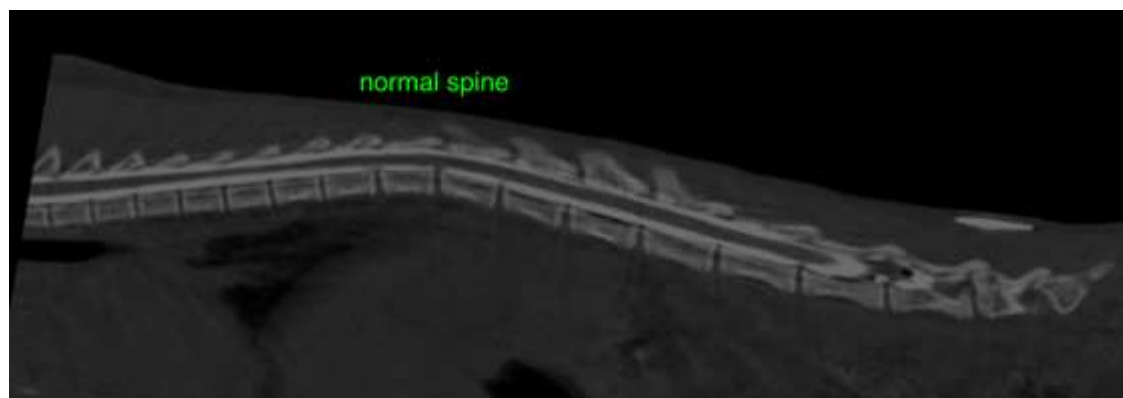Rescue

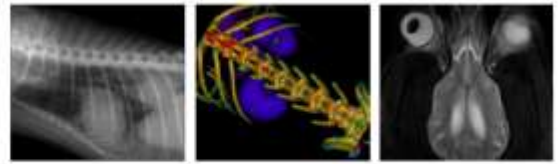
INVOICE

49443

DATE

1-10-22





PATIENT

Cecil NYC Teens for
Animals

The information and recommendations provided are based on the images presented by the referring veterinarian. No evaluation can be communicated regarding pathology that was not visible in the image/video clips provided.

Thank you for this referral. If the clinical or image interpretation does not parallel your findings or if I can be of any further assistance please contact me.

SPECIES

Feline

Sebastian Schaub, Sebastian Schaub, DVM, Dr. med. vet. DipECVDI
sebast.schaub@gmail.com

BREED

DSH

SEX

Female Spayed

AGE

7 Months

INTERPRETED BY

Sebastian Schaub, DVM
Dr. med. vet. DipECVDI

HOSPITAL NAME

Animal Surgical
Center

REFERRING VET

Rescue

INVOICE

49443

DATE

1-10-22