

**PATIENT**

Buddy Inglese

**PRESENTING CLINICAL SIGNS**

Buddy presented for mass on thoracic inlet and one behind the right front leg. This was first noted on throat a few months ago. Previous diagnostics were obtained and revealed they are non malignant.

**SPECIES**

Canine

**COMPUTED TOMOGRAPHY OF THE NECK AND THORAX**

A high resolution post-contrast CT study of the thorax is provided for review.

**BREED**

Yorkshire Terrier Mix

**COMPUTED TOMOGRAPHIC FINDINGS**

In the subcutaneous tissue at the right dorsal aspect of C2, a well-defined, ovoid shaped nodule is visible, measuring up to 9 mm in size.

**SEX**

Male Neuter

Medial to the left sternocephalic muscle, along the left ventral aspect of the neck, a well-defined, uniform fat attenuating mass, measuring approximately 10.4 x 4.5 x 8.7 cm in size is visible. The mass is extending from the level of C2 caudally up to C6. The tracheal and left common carotid artery are deviated to the right by the mass effect. The sternocephalic muscle is deviated laterally. The fat-attenuating mass is demarcated by a thin, soft tissue attenuating capsule.

**AGE**

8 Years

The left thyroid gland is mildly deviated cranially by the mass effect.

**INTERPRETED BY**

Sebastian Schaub, DVM  
Dr. med. vet. DipECVDI

A large lipoma is seen along the right thoracic wall, extending from the caudal aspect of the right hind limb caudally, along the right thoracic wall, measuring 11.0 x 3.2 x 9.8 cm in size.

The sternal, cranial mediastinal and tracheobronchial lymph nodes are small elongated with a normal short-to-long-axis-ratio is < 0.5, the attenuation and contrast enhancement pattern is uniform and considered within normal limits.

**HOSPITAL NAME**

Animal Surgical  
Center

The cardiovascular structures including the pulmonary vasculature are within normal limits.

The cranial lung lobes are consolidated and present a moderately reduced volume.

Small incidental gas pockets are seen within the esophageal lumen, there is no evidence of abnormal dilation.

**REFERRING VET**

Banfield Farmingdale

A small metal attenuating linear foreign body is visible in the right cranial abdomen – level with the pancreas, measuring 1.4 cm in length

**COMPUTED TOMOGRAPHIC DIAGNOSIS****INVOICE**

49444

- Large lipoma left ventral aspect of the neck and right thoracic wall
- Non-specific subcutaneous nodule craniodorsal aspect of the neck
- Dystelectasis of the lung – no evidence of pulmonary metastatic disease
- Incidental migrating foreign body (wire) cranial abdomen

**DATE**

1-10-22

**INTERPRETATION OF THE FINDINGS & FURTHER RECOMMENDATIONS**



**PATIENT**

Buddy Inglese

The masses along the left ventral aspect of the neck and along the right thoracic wall are consistent with large lipomas. There is no evidence of infiltrative growth and complete surgical excision of the lipomas is feasible.

**SPECIES**

Canine

**BREED**

Yorkshire Terrier Mix

**SEX**

Male Neuter

**AGE**

8 Years

**INTERPRETED BY**

Sebastian Schaub, DVM  
Dr. med. vet. DipECVDI

**HOSPITAL NAME**

Animal Surgical  
Center

**REFERRING VET**

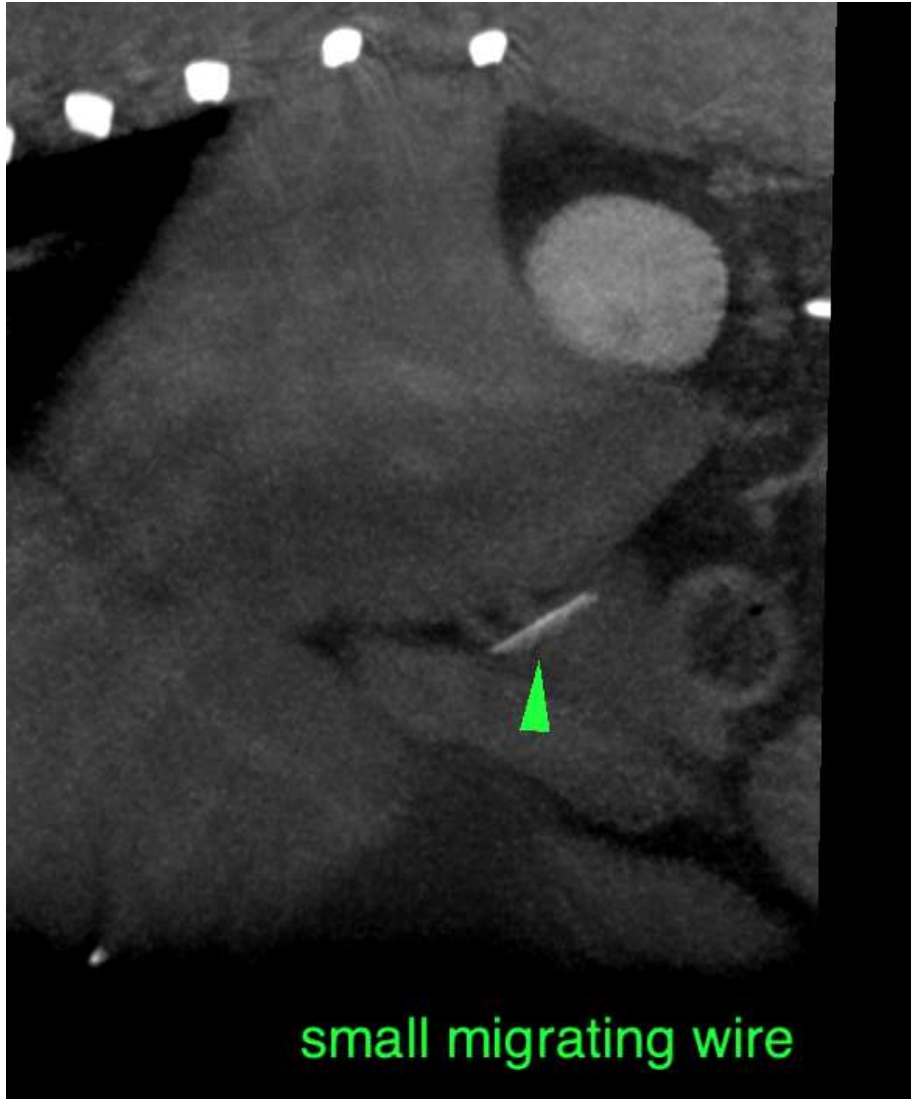
Banfield Farmingdale

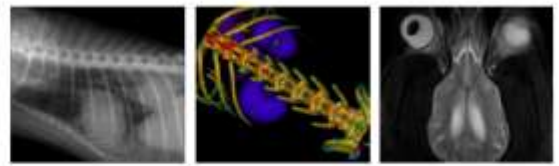
**INVOICE**

49444

**DATE**

1-10-22





**PATIENT**

Buddy Inglese

**SPECIES**

Canine

**BREED**

Yorkshire Terrier Mix

**SEX**

Male Neuter

**AGE**

8 Years

**INTERPRETED BY**

Sebastian Schaub, DVM  
Dr. med. vet. DipECVDI

**HOSPITAL NAME**

Animal Surgical  
Center

**REFERRING VET**

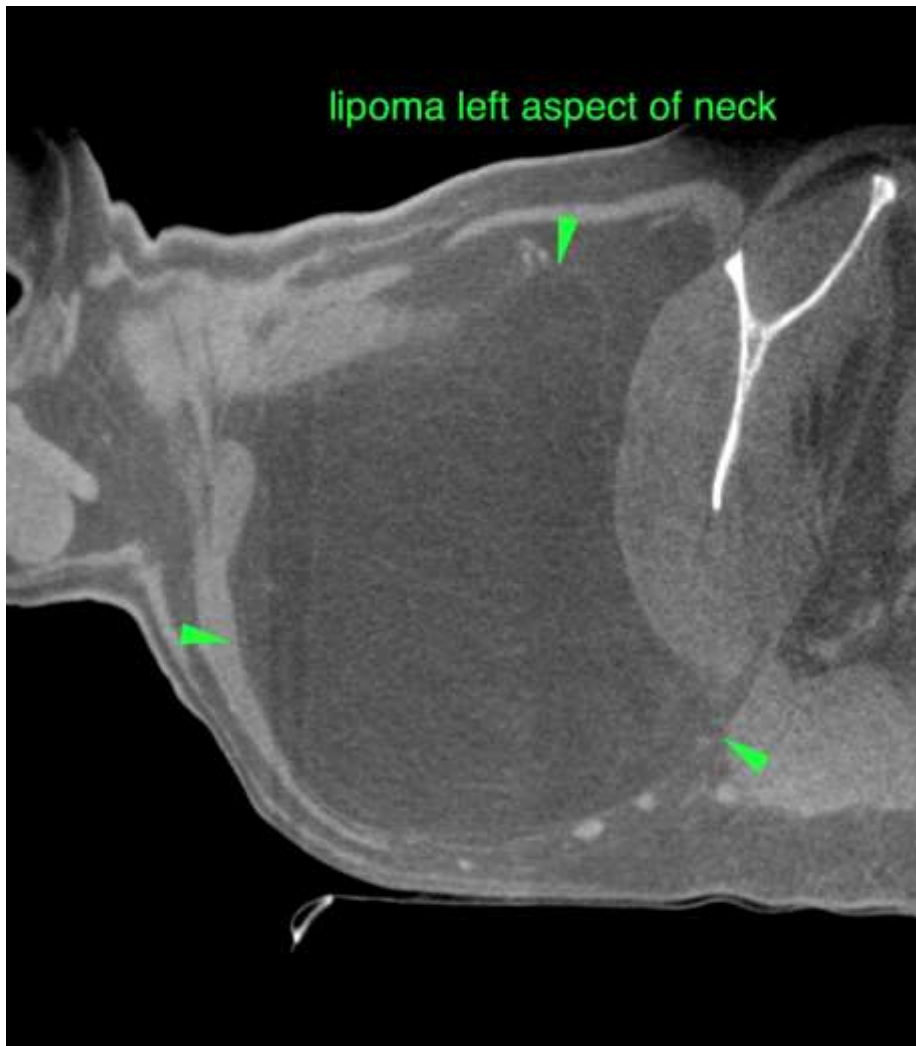
Banfield Farmingdale

**INVOICE**

49444

**DATE**

1-10-22





**PATIENT**

Buddy Inglese

**SPECIES**

Canine

**BREED**

Yorkshire Terrier Mix

**SEX**

Male Neuter

**AGE**

8 Years

**INTERPRETED BY**

Sebastian Schaub, DVM  
Dr. med. vet. DipECVDI

**HOSPITAL NAME**

Animal Surgical  
Center

**REFERRING VET**

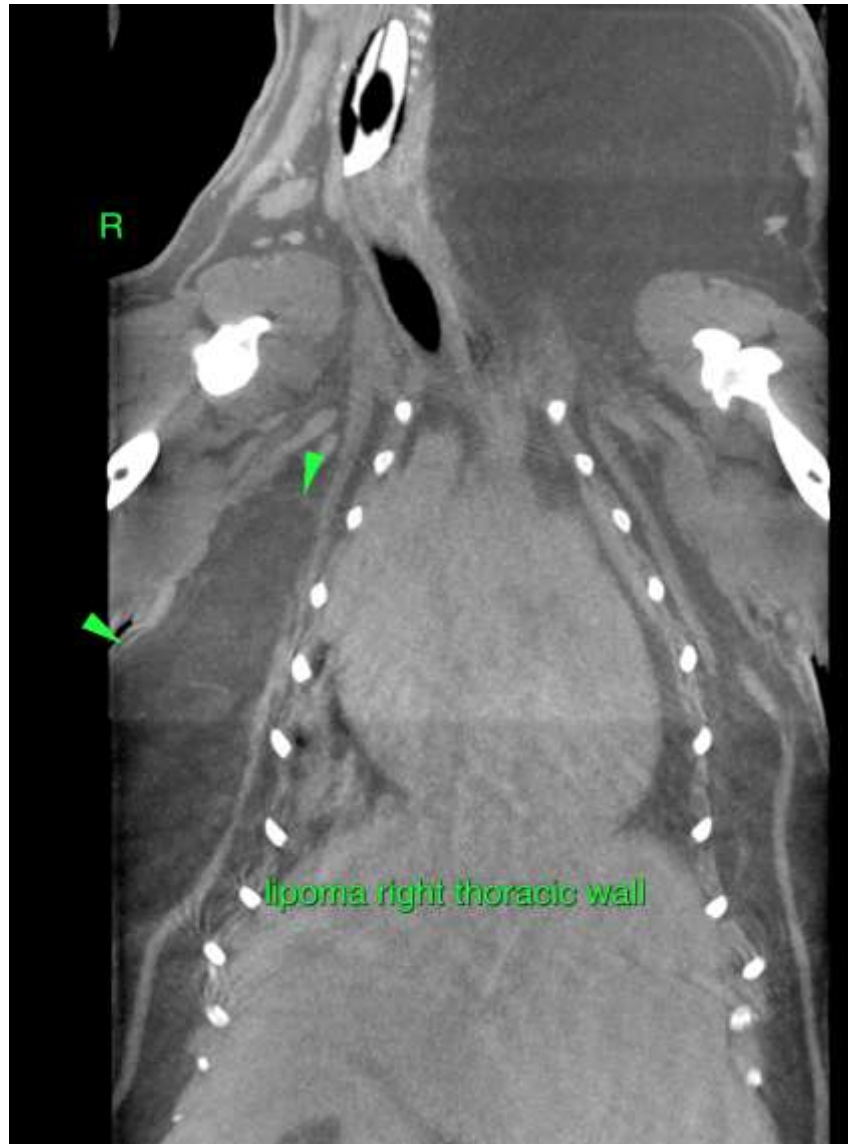Banfield Farmingdale

**INVOICE**

49444

**DATE**

1-10-22



The information and recommendations provided are based on the images presented by the referring veterinarian. No evaluation can be communicated regarding pathology that was not visible in the image/video clips provided.

Thank you for this referral. If the clinical or image interpretation does not parallel your findings or if I can be of any further assistance please contact me.

**Sebastian Schaub**, Sebastian Schaub, DVM, Dr. med. vet. DipECVDI  
sebast.schaub@gmail.com