



PATIENT

Bo Ojeda

PRESENTING CLINICAL SIGNS

Acute coughing and weight loss, P has history of asthma has not been an issue for P in years, P has lost 2.8 pounds in 1 year, P has had a murmur since a young age
Abnormal PE/Chem/CBC/UA Results: lymphopenia 495, otherwise cbc/chem/UA/T4 normal

SPECIES

Feline

RADIOGRAPHIC STUDY OF THE THORAX

Radiographs of the thorax in three imaging planes are provided for review.

BREED

DLH

RADIOGRAPHIC FINDINGS

The costal cartilages are diverging.

SEX

The extrathoracic soft tissues present homogeneous without abnormalities.

MN

The heart is of normal size and shape, there is no evidence of cardiac chamber or vascular enlargement. The pulmonary vasculature is within normal limits.

AGE

15.5 Years

The trachea is normal in diameter and presents the anticipated course. The luminal outline of the trachea is smooth.

INTERPRETED BY

Sebastian Schaub, DVM
Dr. med. vet. DipECVDI

Multifocal mild to moderate peribronchial cuffing is noted throughout the lung field. There is a mild increased distance between the heart and the diaphragm, and the diaphragmatic cupola is mildly flattened in the lateral projection.

The lung parenchyma presents the expected architecture and opacity; the intrapulmonary vascular branching is seen up to the third order lung vessels.

HOSPITAL NAME

Boca Park Animal Hospital

RADIOGRAPHIC DIAGNOSIS

- Bronchial lung pattern with signs for mild air-trapping
- No evidence of cardiac enlargement

REFERRING VET

Laura Warren

INTERPRETATION OF THE FINDINGS & FURTHER RECOMMENDATIONS

The bronchial lung pattern and the signs for mild air-trapping are consistent with feline asthma/feline bronchial disease. Potential bacterial or viral superinfection might have deteriorated clinical signs.

INVOICE

49437

If not done so yet, a cardiac echo might be used for further workup of the cardiac murmur.

No abnormalities are appreciated, explaining the weight loss.

DATE

1-10-22



PATIENT

Bo Ojeda

SPECIES

Feline

BREED

DLH

SEX

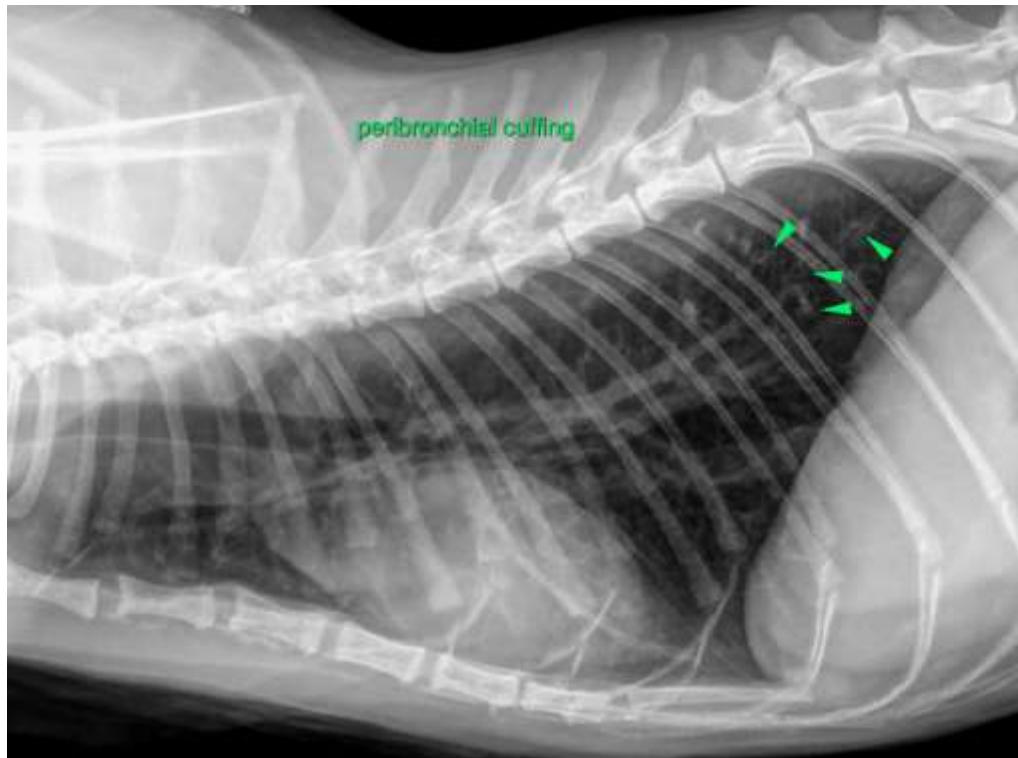
MN

AGE

15.5 Years

INTERPRETED BY

Sebastian Schaub, DVM
Dr. med. vet. DipECVDI



HOSPITAL NAME

Boca Park Animal
Hospital

REFERRING VET

Laura Warren

INVOICE

49437

DATE

1-10-22

The information and recommendations provided are based on the images presented by the referring veterinarian. No evaluation can be communicated regarding pathology that was not visible in the image/video clips provided.

Thank you for this referral. If the clinical or image interpretation does not parallel your findings or if I can be of any further assistance please contact me.

Sebastian Schaub, Sebastian Schaub, DVM, Dr. med. vet. DipECVDI
sebast.schaub@gmail.com