



PATIENT

Wonjo Chen

SPECIES

Feline

BREED

Siamese

SEX

Neutered Male

AGE

15

WEIGHT

5

INTERPRETED BY

Sebastian Schaub, DVM
Dr. med. vet. DipECVDI

IMAGING PERFORMED BY

David

HOSPITAL NAME

Animal Surgical Center
(Oceanside)

REFERRING VET

Dr. Kam

INVOICE

72008

DATE

1/1/26

PRESENTING CLINICAL SIGNS

3x3 cm firm mass attached to the caudal aspect of the ramus of the right mandible, azotemia, mild hyperthyroidism.

COMPUTED TOMOGRAPHIC STUDY OF THE SKULL & THORAX

A high resolution pre- and post-contrast CT study of the skull and abdomen and a post-contrast CT study of the thorax is provided for review.

COMPUTED TOMOGRAPHIC FINDINGS

Skull

All teeth but the mandibular incisors are absent. Multiple retained roots are appreciated in all four jaw quadrants.

Mild destruction of the nasal conchal structures is appreciated. The nasal cavity presents the expected aerated spaces between thin & even conchae and turbinates with smooth mucosal lining.

Both temporomandibular joints present congruent joint spaces with even subchondral bone surfaces and are considered within normal limits.

Both tympanic bullae are aerated, the mucosal lining is not seen, the bony wall is smooth and thin. The external ear canals are within normal limits.

In the right caudal aspect of the cranial fossa – level with the right occipital lobe – a punctuate mineralization is seen; measuring 3 mm. There appears to be left sided deviation of the caudal segment of the falx cerebri.

In the right submandibular region – level with the right mandibular salivary gland – an ill-defined, uniform soft tissue attenuating, roundish mass is seen; measuring approximately 4.1 x 2.7 x 3.6 cm.

Level with the right thyroid gland, a uniform soft tissue attenuating nodule is seen; measuring 8 x 6 x 23 mm.

Thorax

The bony and surrounding soft tissue structures are within normal limits.

The sternal, cranial mediastinal and tracheobronchial lymph nodes are small elongated with a normal short-to-long-axis-ratio is < 0.5, the attenuation and contrast enhancement pattern is uniform and considered within normal limits.

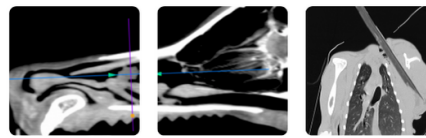
The cardiovascular structures including the pulmonary vasculature are within normal limits.

Multifocal throughout the periphery of the lung, a tree-in-bud pattern – that appears to be centered on peripheral bronchi and partially with interspersed mineralization is seen. Some of the nodular appearing lesions cannot be clearly associated with the bronchial tree.

Small incidental gas pockets are seen within the esophageal lumen, there is no evidence of abnormal dilation.

COMPUTED TOMOGRAPHIC DIAGNOSIS

- Large soft tissue mass right submandibular region
- Suspect intracranial mass right caudal aspect of the cranial fossa with central dystrophic mineralization



PATIENT

Wonjo Chen

- 'Tree-in-bud' pattern of the lung along with a structured nodular interstitial lung pattern
- Enlarged right thyroid gland
- History of dental extractions

SPECIES

Feline

BREED

Siamese

SEX

Neutered Male

AGE

15

WEIGHT

5

INTERPRETED BY

Sebastian Schaub, DVM
Dr. med. vet. DipECVDI

IMAGING PERFORMED BY

David

HOSPITAL NAME

Animal Surgical Center
(Oceanside)

REFERRING VET

Dr. Kam

INVOICE

72008

DATE

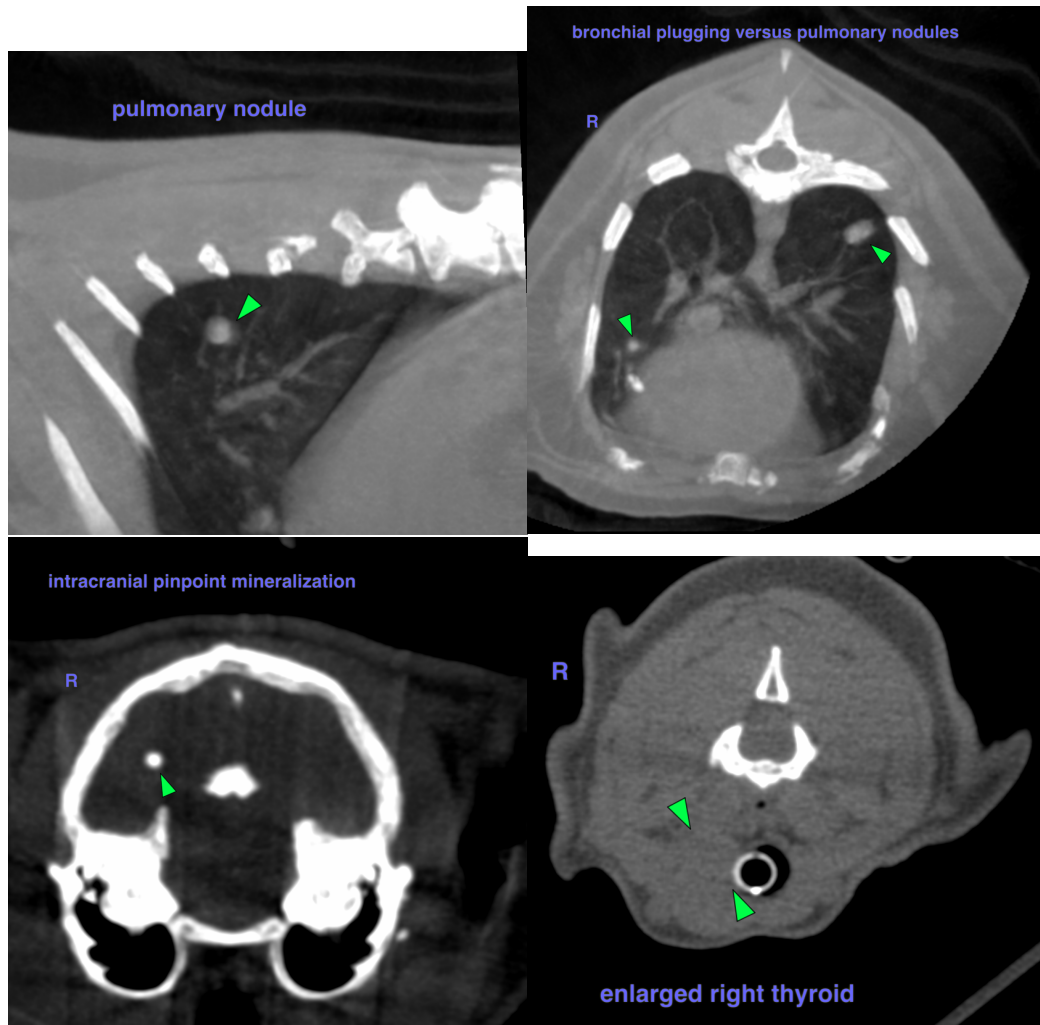
1/1/26

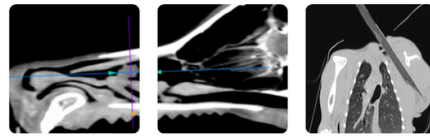
INTERPRETATION OF THE FINDINGS & FURTHER RECOMMENDATIONS

The right submandibular soft tissue mass is suggestive for primary soft tissue neoplasia – possibly of the right mandibular salivary gland. Potentials include adenocarcinoma, fibrosarcoma, round cell tumor, other. Theoretically a cavitary lesion such as sialocele, cyst or abscess are potentials. FNA sampling can be performed for specification.

The intracranial mineralization along with the supposed mass effect in the right caudal aspect of the cranial fossa is highly suggestive for an intracranial mass and meningioma is the top differential. A post contrast CT series can be performed for confirmation.

The tree-in-bud pattern is commonly a sequela to feline bronchial disease with bronchial mucus plugging. Not all nodules can be associated with the bronchial tree and a nodular lung pattern due to pulmonary metastatic disease or primary bronchogenic neoplasm is likely.





PATIENT

Wonjo Chen

SPECIES

Feline

BREED

Siamese

SEX

Neutered Male

AGE

15

WEIGHT

5

INTERPRETED BY

Sebastian Schaub, DVM
Dr. med. vet. DipECVDI

IMAGING PERFORMED BY

David

HOSPITAL NAME

Animal Surgical Center
(Oceanside)

REFERRING VET

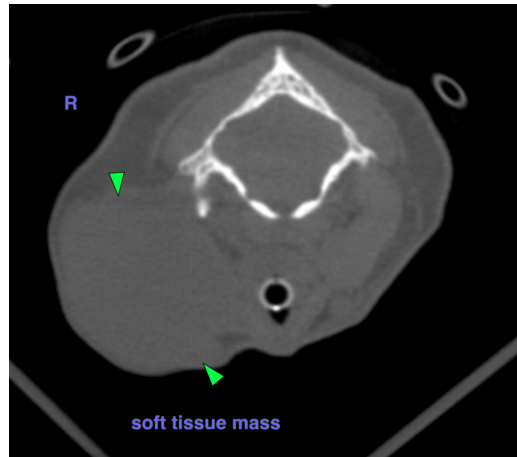
Dr. Kam

INVOICE

72008

DATE

1/1/26



The information and recommendations provided are based on the images presented by the referring veterinarian/sonographer. No evaluation can be communicated regarding pathology that was not visible in the image/video clips provided.

Thank you for this referral. If the clinical or image interpretation does not parallel your findings or if I can be of any further assistance please contact me.

Sebastian Schaub, DVM, Dr. med. vet. DipECVDI
info@sonopath.com