

PATIENT PRESENTING CLINICAL SIGNS

Rofl Rouleau History: Sneezing issue and bloody nasal discharge noticed February 2021, was on multiple doses of Doxycycline and cerenia for nasal decongestant, having breathing issues on and off. Some improvement with medication. June 2021 painful around head area - Metacam, Gabapentin and Robaxin dispensed, bloodwork NAF, Tobramycin dispensed for swollen eye - improvement after this. Dental done in July with extractions. Low dose oral steroids' done - no improvement.

SPECIES

Canine

RADIOGRAPHIC STUDY OF THE TEETH

BREED

Shih Tzu X

Radiographs present a significant heterogeneous bone texture of the maxillary and mandibular bone with a mixed sclerotic and partially lytic pattern. There is severe horizontal loss of alveolar bone recognized throughout showing poorly defined/resorptive margins to the roots of the residual teeth. 104 for example shows moderate resorptive changes with defects of dentin and peripheral bone lysis. 208 impresses with severe root/alveolar lysis and a crown defect. The rostral maxillary projection reveals an asymmetric opacity of the nasal cavities with a higher density on the left side and a missing 204.

SEX

Neutered Male

AGE

13 Years

RADIOGRAPHIC DIAGNOSIS

- Different grades of resorptive changes of the residual teeth with signs of partially severe osteomyelitis of the maxillary and mandibular bone
- Left sided "dental" rhinitis is suspected

INTERPRETED BY

Sebastian Jawinski,
German Board
Certified Vet Specialist
in Diagnostic Imaging

INTERPRETATION OF THE FINDINGS & FURTHER RECOMMENDATIONS

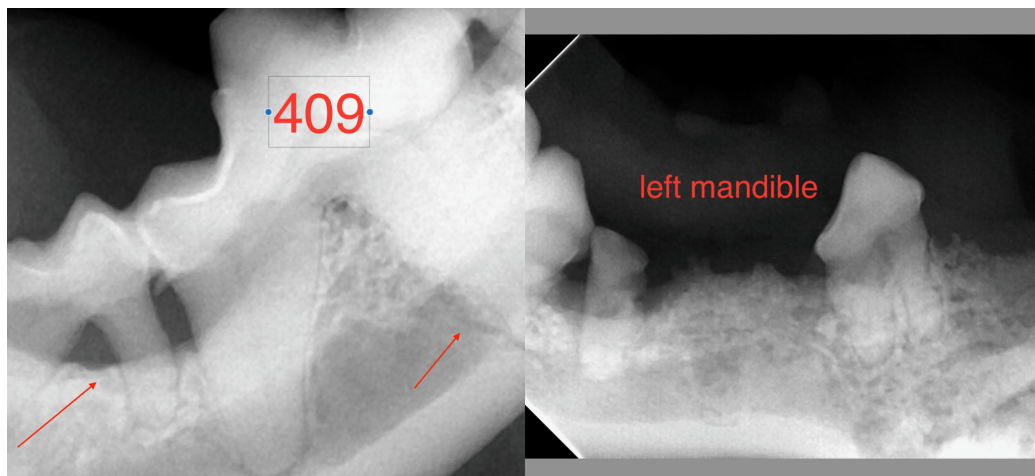
The radiographic findings are severe and involve all displayed teeth. Changes are consistent with advanced CORL and secondary severe and chronic, infectious osteomyelitis is likely. Findings must be correlated with the clinical presentation. Extraction of all teeth is recommended from a radiographic point of view with additional microbiological testing and histopathologic examination of 208 (cave pathologic fracture mandibula).

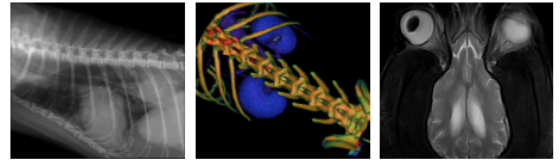
HOSPITAL NAME

REFERRING VET

INVOICE

DATE





PATIENT

Rofl Rouleau

SPECIES

Canine

BREED

Shih Tzu X

SEX

Neutered Male

AGE

13 Years

INTERPRETED BY

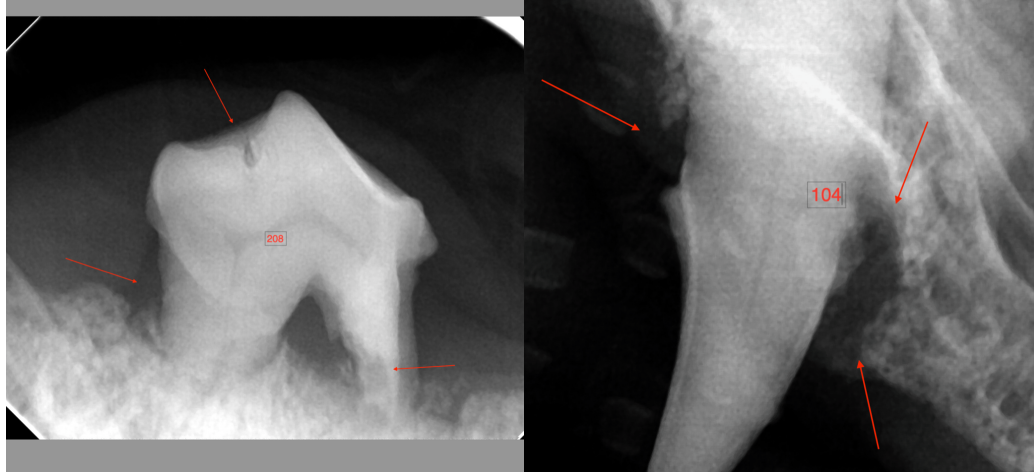
Sebastian Jawinski,
German Board
Certified Vet Specialist
in Diagnostic Imaging

HOSPITAL NAME

REFERRING VET

INVOICE

DATE



The information and recommendations provided are based on the images presented by the referring veterinarian. No evaluation can be communicated regarding pathology that was not visible in the image/video clips provided.

Thank you for this referral. If the clinical or image interpretation does not parallel your findings or if I can be of any further assistance please contact me.

Sebastian Jawinski, German Board Certified Vet Specialist in Diagnostic Imaging
info@sonopath.com