



PATIENT PRESENTING CLINICAL SIGNS

Cohen Luttrell History: Chronic elevation of liver values, high bile acids

COMPUTED TOMOGRAPHIC STUDY OF THE ABDOMEN

SPECIES

Canine The liver presents expected size, surfaces and shape. The contrast study reveals a mild and non-specific periportal halo sign. The gallbladder is inconspicuous without evidence of cholestasis. The common bile duct is considered to be normal. Caudal vena cava and portal vein appear normal without signs of a PSS.

BREED

Labradoodle The spleen shows normal findings in terms of size, surface, shape and contrast behavior.

SEX

Neutered Male Unremarkable presentation of the bilaterally symmetrical kidneys.

Adrenal glands are in normal limits.

AGE

4 Years As far as can be assessed, the stomach and all parts of intestine are regularly presented without any indication of a wall thickening or a mass.

Ureters, urinary bladder and trigone are normal.

INTERPRETED BY

Sebastian Jawinski,
German Board
Certified Vet Specialist
in Diagnostic Imaging

Abdominal lymph nodes and abdominal vessels have no particular findings. Signs of peritoneal/retroperitoneal effusion or free gas are not recognized.

COMPUTED TOMOGRAPHIC DIAGNOSIS

- Normal findings of the abdomen

HOSPITAL NAME

Animal Health
Partners

INTERPRETATION OF THE FINDINGS & FURTHER RECOMMENDATIONS

CT morphology of the liver and the portal vein/caudal vena cava are inconspicuous. The mild periportal halo is commonly an incidental finding without further relevance and is sometimes detected with liver congestion due to right heart disease. The latter is not suspected in this case. Diffuse or infiltrative liver/hepatocellular disease is still possible as well as non-hepatic issues such as IBD or pancreatitis.

REFERRING VET

Dr. Shannon
Westgarth

Consider liver FNA/biopsy.

INVOICE

13305

DATE

9/27/21



PATIENT

Cohen Luttrell

SPECIES

Canine

BREED

Labradoodle

SEX

Neutered Male

AGE

4 Years

INTERPRETED BY

Sebastian Jawinski,
German Board
Certified Vet Specialist
in Diagnostic Imaging

HOSPITAL NAME

Animal Health
Partners

REFERRING VET

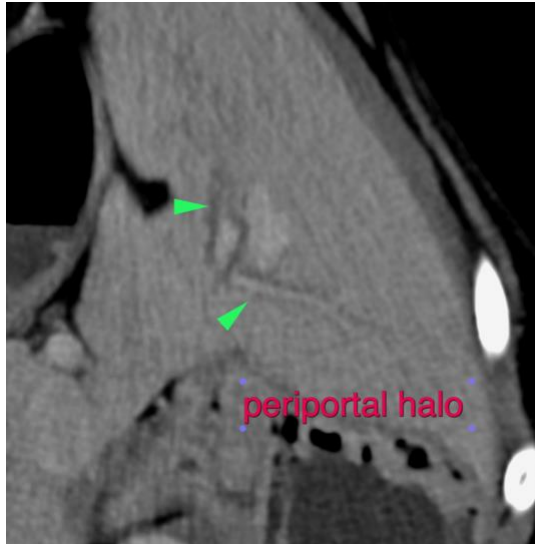
Dr. Shannon
Westgarth

INVOICE

13305

DATE

9/27/21



The information and recommendations provided are based on the images presented by the referring veterinarian. No evaluation can be communicated regarding pathology that was not visible in the image/video clips provided.

Thank you for this referral. If the clinical or image interpretation does not parallel your findings or if I can be of any further assistance please contact me.

Sebastian Jawinski, German Board Certified Vet Specialist in Diagnostic Imaging
info@sonopath.com