



PATIENT

Sophie Robinson

PRESENTING CLINICAL SIGNS

vomiting once or twice daily started 3 days ago, started undigested food then bile. Black tarry stool started 3 days ago. Activity level less than normal. Not eating. Heart murmur grade 2/6. No coughing. Owner moved to a new house 3 weeks ago.

SPECIES

Canine

Abnormal PE/Chem/CBC/UA Results: Blood work indicate mild dehydration, stress glucose, increase in Lipase, mild increase in Total Bilirubin, K. normal high 5.1, Sod normal low 141 (141-152), Na/K ratio 27.6, otherwise unremarkable.

BREED

Chihuahua

RADIOGRAPHIC FINDINGS

Displayed bony structures of spine and thorax are within normal limits without signs of a fracture, sub-/luxation and/or a lytic/sclerotic process.

SEX

Female Spayed

Thorax:

There is no evidence of cardiovascular disease. Lung shows regular density, no evidence of focal/nodular lesions. Trachea is unremarkable in diameter and course and shows age- and breed-appropriate calcifications as well as the main stem bronchi.

AGE

12 Years

Mediastinum presents expected soft tissue density, there is no evidence of tracheobronchial, cranial mediastinal or sternal lymphadenopathy. No mediastinal shift is seen.

INTERPRETED BY

Sebastian Jawinski,
German Board
Certified Vet
Specialist in
Diagnostic Imaging

Esophagus is not visible and considered to be normal.

Diaphragm is unremarkable, no signs of pleural effusion.

Abdomen:

Liver and spleen present as expected and are well defined. The area of the gallbladder presents multiple granular-like calculi.

Stomach and intestines are predominantly empty with some gas filling of the stomach and small intestine. Intestinal loops reveal partially hyperperistaltic. In both lateral projections the pylorus appears distended with prominent rugae and a thickened wall. The colon is mildly gas distended and presents a subjectively thickened wall and contains residuals of ingesta.

Both kidneys are not well visualized but considered to be normal.

HOSPITAL NAME

St. Catherine's Animal
Hospital

REFERRING VET

Dr. Bekhit

INVOICE

47496

No signs of abdominal or retroperitoneal effusion.

Urinary bladder is mildly filled, no evidence of radiopaque cystic calculi.

DATE

9-22-21

**PATIENT**

Sophie Robinson

SPECIES

Canine

BREED

Chihuahua

SEX

Female Spayed

AGE

12 Years

INTERPRETED BY

Sebastian Jawinski,
German Board
Certified Vet
Specialist in
Diagnostic Imaging

HOSPITAL NAME

St. Catherine's Animal
Hospital

REFERRING VET

Dr. Bekhit

INVOICE

47496

DATE

9-22-21

RADIOGRAPHIC DIAGNOSIS

- Normal findings of the thorax
- Signs of a gastroenteritis including all parts of the intestines
- Cholelithiasis

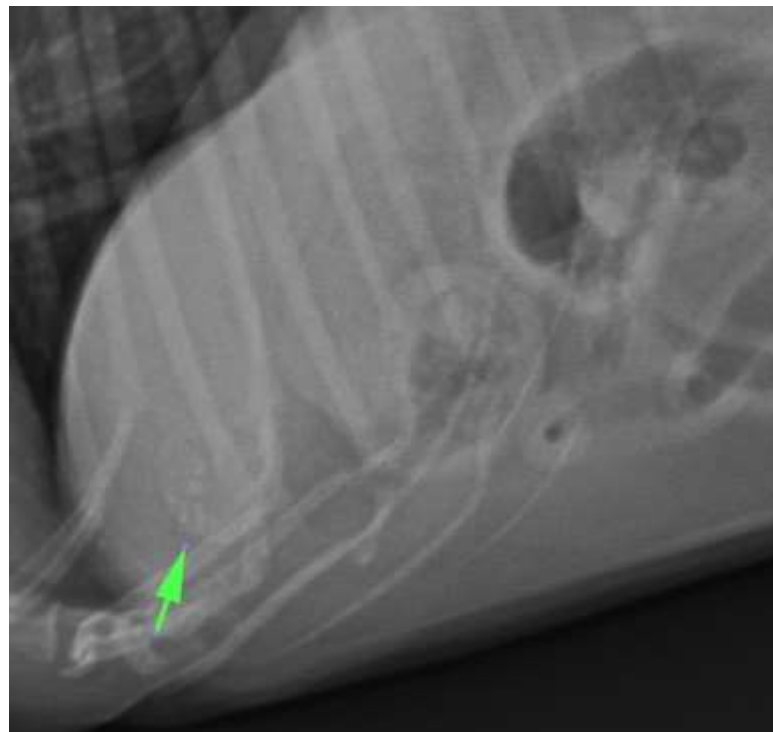
INTERPRETATION OF THE FINDINGS & FURTHER RECOMMENDATIONS

Normal appearance of the heart and the pulmonary structures does not fully exclude degenerative valve disease. Currently signs of a congestive heart failure and cardiomegaly are missing.

The gastrointestinal tract is predominantly empty showing some gas distension and indicated hyperperistaltic loops which is consistent with unspecific inflammatory/infectious bowel disease. I favor the latter. The distended pylorus could go along with gastritis/duodenitis. Thickening of the wall could indicate gastric obstruction/stenosis. Radiopaque foreign material is not noted. A severe inflammatory process such as peritonitis and pancreatitis are not recognized.

The suspected cholelithiasis commonly is an incidental finding. However, cholelithiasis/ cholangitis with secondary cholestasis, pancreatitis and duodenitis are potential differentials.

I would recommend a complementary abdominal ultrasound if symptoms do not improve.





PATIENT

Sophie Robinson

SPECIES

Canine

BREED

Chihuahua

SEX

Female Spayed

AGE

12 Years

INTERPRETED BY

Sebastian Jawinski,
German Board
Certified Vet
Specialist in
Diagnostic Imaging

HOSPITAL NAME

St. Catherine's Animal
Hospital

REFERRING VET

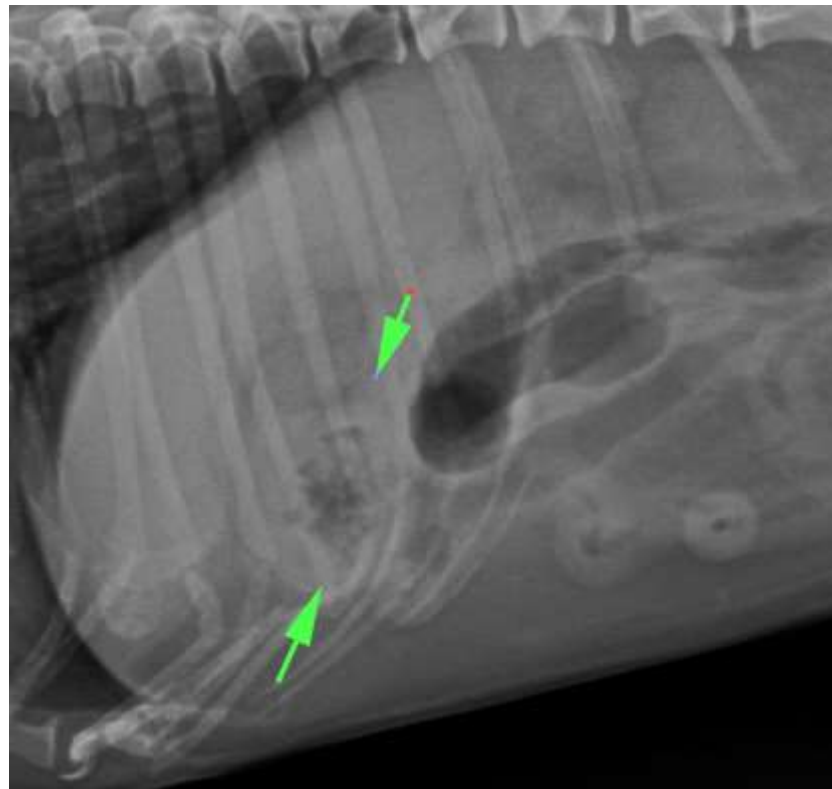
Dr. Bekhit

INVOICE

47496

DATE

9-22-21



The information and recommendations provided are based on the images presented by the referring veterinarian. No evaluation can be communicated regarding pathology that was not visible in the image/video clips provided.

Thank you for this referral. If the clinical or image interpretation does not parallel your findings or if I can be of any further assistance, please contact me.

Sebastian Jawinski, German Board Certified Vet Specialist in Diagnostic Imaging
Sebastian.Jawinski@sonopath.com