

**PATIENT**

Molly Reid

**PRESENTING CLINICAL SIGNS**

Coughing. Grade 3/6 right sided murmur. Difficulty auscultating left side of chest. RR=40

**SPECIES**

Canine

**RADIOGRAPHIC STUDY OF THE THORAX**

Right/left lateral and vd views provided for review.

**RADIOGRAPHIC FINDINGS****BREED**

Jap Chin

The surrounding bony structures are within age-appropriate limits. The extra-thoracic soft tissues are homogenous without abnormalities. The left kidney shows renal calculi as an incidental finding.

**SEX**

Spayed Female

The cardiac silhouette is not clearly defined and silhouettes with pleural effusion, but cardiomegaly is suspected with severe dorsal elevation of the trachea. The vd projection reveals a mass effect and pleural effusion of the left cranial hemithorax leading to mediastinal/tracheal shift to the right.

**AGE**

15

Lungs on the left are retracted. The right lobes show regular ventilation and density.

The diaphragm is inconspicuous.

**INTERPRETED BY**

Sebastian Jawinski,  
German Board  
Certified Vet  
Specialist in  
Diagnostic Imaging

**RADIOGRAPHIC DIAGNOSIS**

- Mass effect left cranial hemithorax with moderate left-sided pleural effusion
- Cardiomegaly

**INTERPRETATION OF THE FINDINGS & FURTHER RECOMMENDATIONS**

The cardiac silhouette appears enlarged and rounded as far as can be assessed. The dorsal elevation of the trachea would go along with that assumption. Additionally, a left sided mass is suspected in the cranial chest leading to a tracheal shift to the right and displacement/retraction of the left lung lobes. Differentials include mediastinal, pleural or pulmonary masses. A cyst/abscess formation are possible as well as neoplasia which I would favor. Next diagnostic steps could be echocardiography and an ultrasound of the left cranial thorax with FNA of the suspected mass and if inconclusive examination of the pleural effusion.

**HOSPITAL NAME**

Pacific Avenue  
Veterinary Clinic

**REFERRING VET**

Sid Bruckert-Frisk

**INVOICE**

47495

**DATE**

9-22-21



**PATIENT**

Molly Reid

**SPECIES**

Canine

**BREED**

Jap Chin

**SEX**

Spayed Female

**AGE**

15

**INTERPRETED BY**

Sebastian Jawinski,  
German Board  
Certified Vet  
Specialist in  
Diagnostic Imaging

**HOSPITAL NAME**

Pacific Avenue  
Veterinary Clinic

**REFERRING VET**

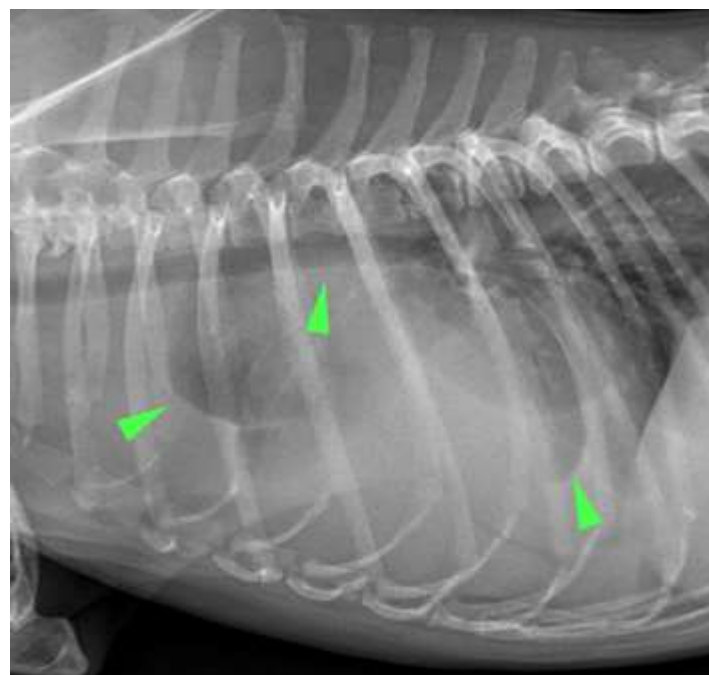
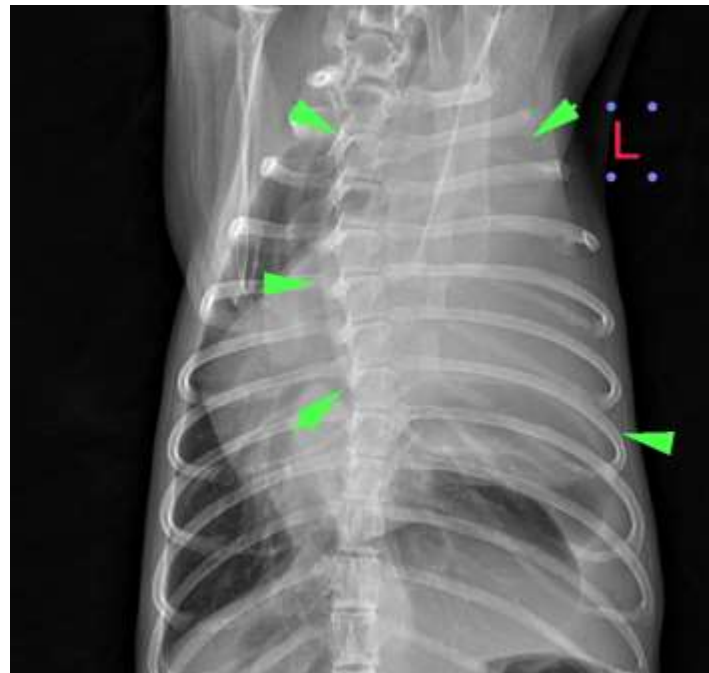
Sid Bruckert-Frisk

**INVOICE**

47495

**DATE**

9-22-21





**PATIENT**

Molly Reid

The information and recommendations provided are based on the images presented by the referring veterinarian. No evaluation can be communicated regarding pathology that was not visible in the image/video clips provided.

**SPECIES**

Canine

Thank you for this referral. If the clinical or image interpretation does not parallel your findings or if I can be of any further assistance, please contact me.

**Sebastian Jawinski, German Board Certified Vet Specialist in Diagnostic Imaging**  
Sebastian.Jawinski@sonopath.com

**BREED**

Jap Chin

**SEX**

Spayed Female

**AGE**

15

**INTERPRETED BY**

Sebastian Jawinski,  
German Board  
Certified Vet  
Specialist in  
Diagnostic Imaging

**HOSPITAL NAME**

Pacific Avenue  
Veterinary Clinic

**REFERRING VET**

Sid Bruckert-Frisk

**INVOICE**

47495

**DATE**

9-22-21