



PATIENT

Bean Pinto

PRESENTING CLINICAL SIGNS

Patient presents for a pre-op CT myelogram of the TL spine. Spinal radiographs revealed significant disk space narrowing diffusely throughout the caudal thoracic spine with multiple congenital vertebral anomalies present. Disk mineralization was identified between the fifth and six lumbar segment and between the third and fourth lumbar segment.

SPECIES

Canine

COMPUTED TOMOGRAPHIC STUDY OF THE THORACIC & LUMBAR SPINE

Pre/post contrast studies as well as myelogram provided for review.

BREED

French Bulldog

COMPUTED TOMOGRAPHIC FINDINGS

Presented bony structures of the spine show severe but breed-appropriate malformations with multiple wedge-shaped hemivertebrae of the thoracic spine and tail. Moderate thoracic kyphosis and scoliosis are recognized.

SEX

FS

Vertebral bodies are of regular density without signs of a lytic or sclerotic process. There is no evidence of a fracture and/or sub-/luxation.

AGE

3 Years, 1 Month

There are multiple calcified nuclei noted.

INTERPRETED BY

Sebastian Jawinski,
German Board
Certified Vet
Specialist in
Diagnostic Imaging

At the level of L2/3 a moderate and broad-based disc herniation is recognized. The disc material is located medial to right-lateral and is distributed mildly cranially and caudally to the intervertebral disc space.

The discs of L3/4 and L5/6 show a mild vacuum phenomenon, mild protrusions are noted throughout the lumbar spine but without relevant compressive signs.

HOSPITAL NAME

South Bay Animal
Hospital

Paravertebral soft tissues are bilaterally symmetrical, especially the course of the femoral and sciatic nerves is inconspicuous.

COMPUTED TOMOGRAPHIC DIAGNOSIS

REFERRING VET

Filippo Adamo,
DECVN

- Moderate disc herniation L2/3, medial to right-lateral with mild compression of the spinal cord
- Multiple degenerative changes of the intervertebral discs and mild protrusions lumbar spine without compressive signs
- Severe but breed-appropriate malformations of the spine with thoracic kyphosis/scoliosis

INVOICE

47497

INTERPRETATION OF THE FINDINGS & FURTHER RECOMMENDATIONS

CT findings show a mild to moderate disc herniation at the level of L2/3 with mild compression of the spinal cord. The cranial and caudal distribution of the disc material indicates an acute herniation, additional hemorrhage and myelopathy are possible but not recognized with CT. This finding must be correlated with the clinical presentation (decompressive surgery hemilaminectomy with a right-sided approach?).

DATE

9-22-21



PATIENT

Bean Pinto

Grade of compression as seen with CT is not compellingly the most relevant clinical finding. Long-term prognosis may be reduced regarding the multiple degenerative findings.

SPECIES

Canine

BREED

French Bulldog

SEX

FS

AGE

3 Years, 1 Month

INTERPRETED BY

Sebastian Jawinski,
German Board
Certified Vet
Specialist in
Diagnostic Imaging

HOSPITAL NAME

South Bay Animal
Hospital

REFERRING VET

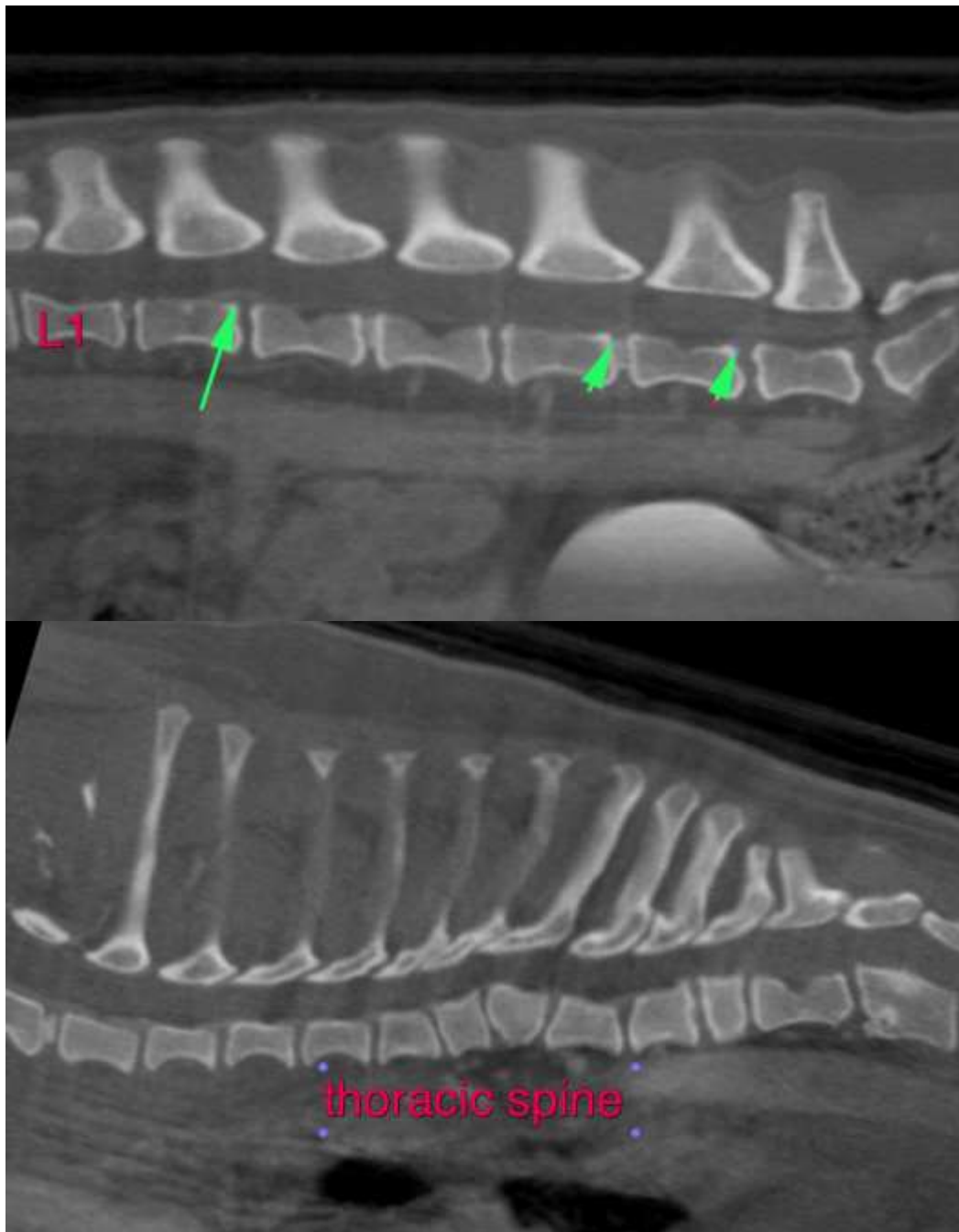
Filippo Adamo,
DECVN

INVOICE

47497

DATE

9-22-21





PATIENT

Bean Pinto

SPECIES

Canine

BREED

French Bulldog

SEX

FS

AGE

3 Years, 1 Month

INTERPRETED BY

Sebastian Jawinski,
German Board
Certified Vet
Specialist in
Diagnostic Imaging

HOSPITAL NAME

South Bay Animal
Hospital

REFERRING VET

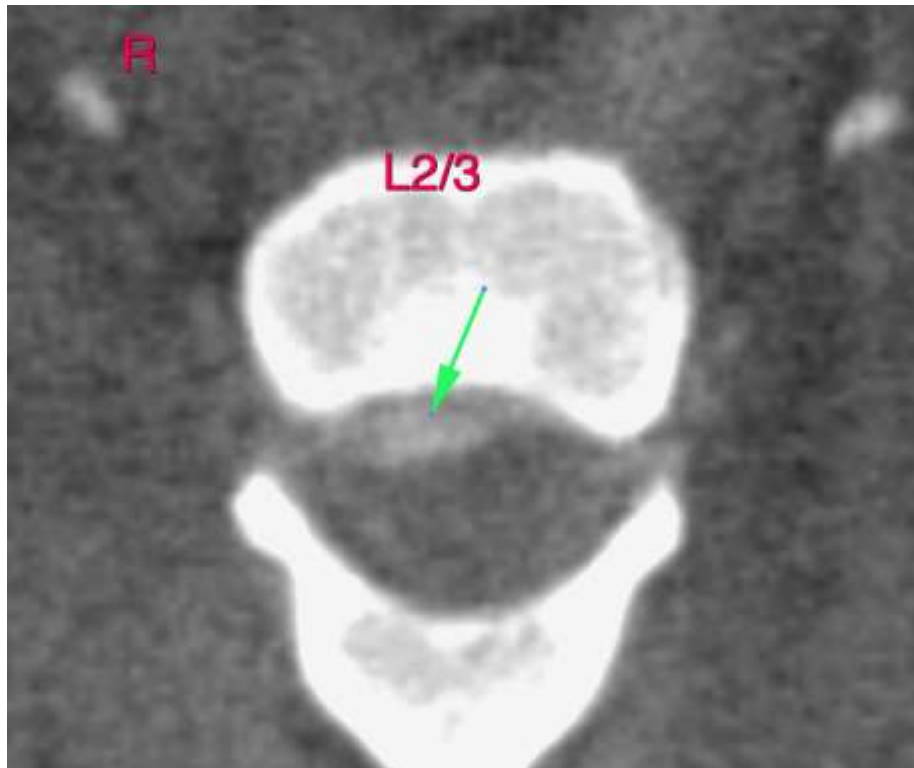
Filippo Adamo,
DECVN

INVOICE

47497

DATE

9-22-21



The information and recommendations provided are based on the images presented by the referring veterinarian. No evaluation can be communicated regarding pathology that was not visible in the image/video clips provided.

Thank you for this referral. If the clinical or image interpretation does not parallel your findings or if I can be of any further assistance, please contact me.

Sebastian Jawinski, German Board Certified Vet Specialist in Diagnostic Imaging
Sebastian.Jawinski@sonopath.com