



PATIENT PRESENTING CLINICAL SIGNS

Teddy Franklyn History: Lethargy, inappetence

SPECIES RADIOGRAPHIC STUDY OF THE ABDOMEN

Canine All displayed bony structures show age-appropriate findings and are inconspicuous.
Liver and spleen both present mildly rounded margins but are well defined.

BREED

Border Collie Mix The stomach is predominantly empty with some gas filing and residual formed ingesta. Gastric axis is inconspicuous. The small intestine partially shows foamy content and marked distension of the ileocolic area. The colon is well filled with radiopaque ingesta, which is normal.

SEX

Neutered Male Both kidneys are not well visualized but considered to be normal.
No signs of abdominal or retroperitoneal effusion.

AGE

12 Years Urinary bladder is moderately filled and presents a focal but poorly margined radiopaque opacity in its central part. Prostate is indicated and considered as normal.

RADIOGRAPHIC DIAGNOSIS

INTERPRETED BY

Sebastian Jawinski,
German Board
Certified Vet Specialist
in Diagnostic Imaging

- Gas distended caecum/ileocolic junction
- Foamy ingesta small intestine
- Well-filled colon
- Mild hepato- and splenomegaly
- Cystic calculi

HOSPITAL NAME

New Bridge VP

INTERPRETATION OF THE FINDINGS & FURTHER RECOMMENDATIONS

Gastric content and the distension of the caecum must be correlated with the time of the last meal and the clinical presentation (local/abdominal pain?). Foreign material is not obvious but cannot be fully excluded. Currently signs of an overt ileus and/or a severe inflammation such as peritonitis/pancreatitis are missing. However, enteritis and migrating foreign material are still possible.

REFERRING VET

Dr. Abina Glennon

There is evidence of cystic calculi/sediment which may be an incidental finding. Hepato-and splenomegaly are very unspecific and commonly seen with liver lipidosis/chronic hepatitis and inflammatory/infectious issues. Their clinical relevance is questionable. If symptoms do not improve I would recommend a complementary abdominal ultrasound.

INVOICE

13213

DATE

9/21/21



PATIENT

Teddy Franklyn

SPECIES

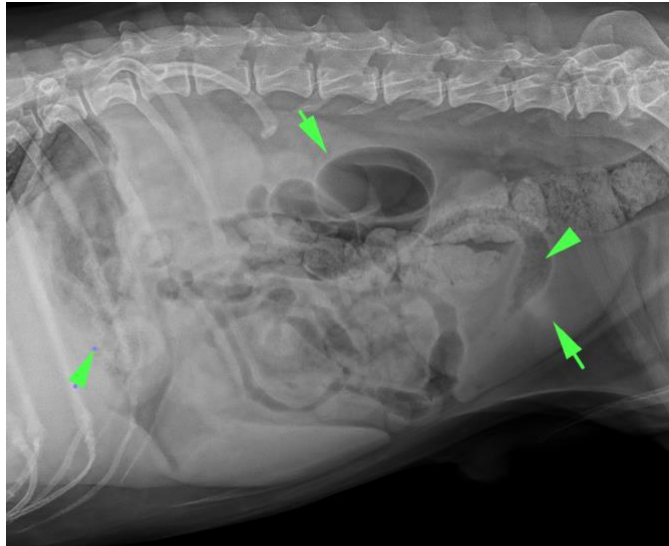
Canine

BREED

Border Collie Mix

SEX

Neutered Male



AGE

12 Years

The information and recommendations provided are based on the images presented by the referring veterinarian. No evaluation can be communicated regarding pathology that was not visible in the image/video clips provided.

Thank you for this referral. If the clinical or image interpretation does not parallel your findings or if I can be of any further assistance please contact me.

INTERPRETED BY

Sebastian Jawinski,
German Board
Certified Vet Specialist
in Diagnostic Imaging

Sebastian Jawinski, German Board Certified Vet Specialist in Diagnostic Imaging
info@sonopath.com

HOSPITAL NAME

New Bridge VP

REFERRING VET

Dr. Abina Glennon

INVOICE

13213

DATE

9/21/21