



PATIENT PRESENTING CLINICAL SIGNS

Rhyme Truax History: Patient has been reverse sneezing/coughing, intermittently having difficulty breathing for past 2-3 days. Pt will freeze in place when having difficulty breathing per Owner. Owner also states that they have had to pry open Pt's mouth to get her to breath again. Owner also states that Pt was lethargic yesterday. Pt also has heart murmur.

SPECIES

Canine Abnormal PE/Chem/CBC/UA Results: Pt has heart murmur

BREED RADIOGRAPHIC STUDY OF THE THORAX

Terrier/Yorkshire The surrounding bony structures are within normal limits. The extra-thoracic soft tissues are homogenous without abnormalities.

SEX The cardiac silhouette appears mildly enlarged with a prominent left atrium. The vertebral heart score equals 10.9.

Spayed Female

The lung density appears normal throughout. There is no evidence of nodular or focal lesions recognized.

AGE

10 Years 1 Month The trachea shows moderate and long stretched narrowing cranial to the thoracic inlet. Transverse diameter is reduced to approximately 70 %. The carina and the bronchial tree are prominent but without relevant collapse in this respiratory phase.

INTERPRETED BY

Sebastian Jawinski,
German Board
Certified Vet Specialist
in Diagnostic Imaging

The mediastinum presents expected soft tissue density, there is no evidence of tracheobronchial, cranial mediastinal or sternal lymphadenopathy. No mediastinal shift is seen.

The esophagus is not visible and considered to be normal.

HOSPITAL NAME

Ahwatukee Commons
VH

The diaphragm is unremarkable, no signs of pleural effusion.

RADIOGRAPHIC DIAGNOSIS

- Mild cardiomegaly with suspected left atrial enlargement
- Moderate and long stretched tracheal collapse is suspected

REFERRING VET

Dr. Rebecca Housley

INTERPRETATION OF THE FINDINGS & FURTHER RECOMMENDATIONS

Radiographs shows mild cardiomegaly and enlargement of the left atrium which is commonly seen with degenerative mitral valve disease. Echocardiograph is recommended for further evaluation. Signs of a congestive heart failure are currently not detected.

INVOICE

13210

DATE

9/21/21

I suspect a long stretched and at least moderate (dynamic) tracheal narrowing/collapse. This finding must be correlated with the clinical presentation. The tracheal narrowing partially could be artificial due to present superimposing with the sub-cervical musculature. Endoscopy could be used to get BAL



PATIENT

Rhyme Truax

for cytology and microbiologic testing. Involvement of the carina and the main stem bronchi cannot be ruled out since they are depending on the respiratory phase. Currently there is no secondary pneumonia recognized.

SPECIES

Canine

BREED

Terrier/Yorkshire

SEX

Spayed Female

AGE

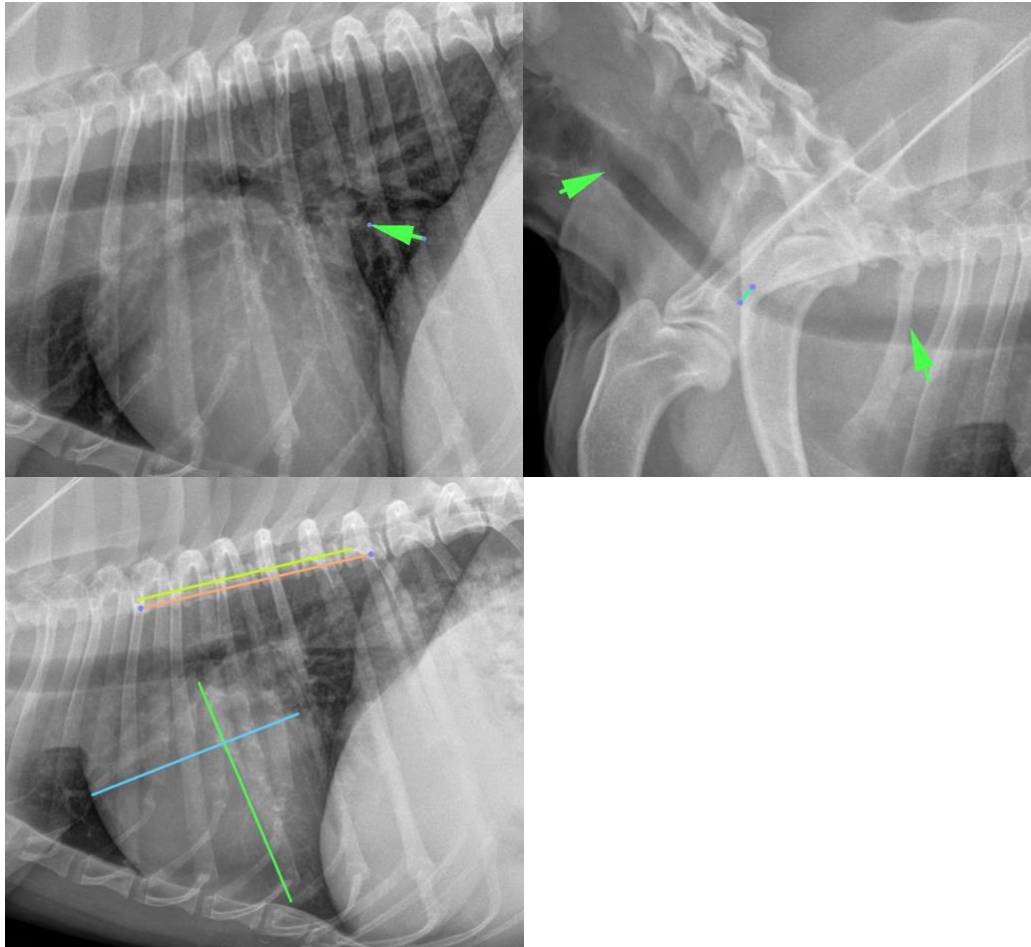
10 Years 1 Month

INTERPRETED BY

Sebastian Jawinski,
German Board
Certified Vet Specialist
in Diagnostic Imaging

HOSPITAL NAME

Ahwatukee Commons
VH



REFERRING VET

Dr. Rebecca Housley

The information and recommendations provided are based on the images presented by the referring veterinarian. No evaluation can be communicated regarding pathology that was not visible in the image/video clips provided.

INVOICE

13210

Sebastian Jawinski, German Board Certified Vet Specialist in Diagnostic Imaging
info@sonopath.com

DATE

9/21/21

Thank you for this referral. If the clinical or image interpretation does not parallel your findings or if I can be of any further assistance please contact me.



PATIENT

Rhyme Truax

SPECIES

Canine

BREED

Terrier/Yorkshire

SEX

Spayed Female

AGE

10 Years 1 Month

INTERPRETED BY

Sebastian Jawinski,
German Board
Certified Vet Specialist
in Diagnostic Imaging

HOSPITAL NAME

Ahwatukee Commons
VH

REFERRING VET

Dr. Rebecca Housley

INVOICE

13210

DATE

9/21/21