

**PATIENT**

Sarge Save a Soul
Rescue North

SPECIES

Canine

BREED

American Pitbull Mix

SEX

MN

AGE

8

INTERPRETED BY

Sebastian Jawinski,
German Board
Certified Vet
Specialist in
Diagnostic Imaging

HOSPITAL NAME

Torch Lake
Veterinary Clinic

REFERRING VET

Adrienne Waffle

INVOICE

47468

DATE

9-20-21

PRESENTING CLINICAL SIGNS

Owner has been treating for sialoadenosis. Presented for 2nd opinion. Currently on 300 mg doxycycline BID; 20 mg pred SID. Bloods in april showed mildly elevated ALT - 149
Abnormal PE/Chem/CBC/UA Results: L head tilt; minimal abduscence bilaterally; upper respiratory stridor; decreased gag; normal PLRs; severe temporal muscle wasting; abducted elbows; previous met check thorax submitted

RADIOGRAPHIC STUDY OF THE NECK / CERVICAL SPINE

Lateral and vd projection provided for review.

RADIOGRAPHIC FINDINGS

There is an ill-defined soft tissue dense opacity silhouetting with the laryngeal structures and the cranial parts of the trachea best seen in the lateral projections. Estimated diameters measure approximately 8.5 x 6.2 cm. Erosion of the laryngeal structures and the trachea is not recognized. The mass is located on the left side.

The presented spine shows a harmonic course with inconspicuous vertebral bodies.

RADIOGRAPHIC DIAGNOSIS

- Ill-defined soft tissue dense mass left neck at the level of the larynx and the cranial trachea

INTERPRETATION OF THE FINDINGS & FURTHER RECOMMENDATIONS

Differentials of the left sided mass include neoplastic and inflammatory lesions as seen with thyroid masses, severe retropharyngeal lymphadenopathy and abscess formation due to infection or foreign material. The latter is not recognized. Lesions of the left mandibular salivary gland are possible as well. Radiographic appearance and location are unspecific. Primary oral neoplasia (tonsil carcinoma, squamous cell carcinoma, etc.) with secondary metastatic retropharyngeal lymphadenomegaly cannot be fully excluded. I would recommend a complementary ultrasound of the neck and oral examination to determine the exact localization and to rule foreign material/an abscess.



PATIENT

Sarge Save a Soul
Rescue North

SPECIES

Canine

BREED

American Pitbull Mix

SEX

MN

AGE

8

INTERPRETED BY

Sebastian Jawinski,
German Board
Certified Vet
Specialist in
Diagnostic Imaging

HOSPITAL NAME

Torch Lake
Veterinary Clinic

REFERRING VET

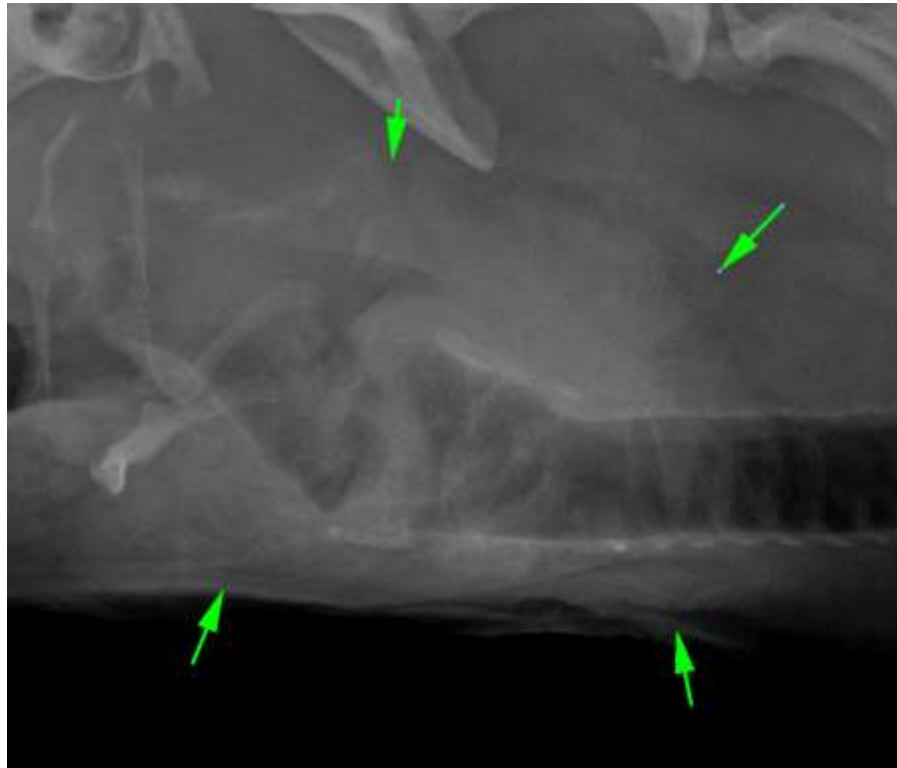
Adrienne Waffle

INVOICE

47468

DATE

9-20-21



The information and recommendations provided are based on the images presented by the referring veterinarian. No evaluation can be communicated regarding pathology that was not visible in the image/video clips provided.

Thank you for this referral. If the clinical or image interpretation does not parallel your findings or if I can be of any further assistance, please contact me.

Sebastian Jawinski, German Board Certified Vet Specialist in Diagnostic Imaging
Sebastian.Jawinski@sonopath.com