



**PATIENT**

Frankie Walsh

**PRESENTING CLINICAL SIGNS**

Hx of back pain and issues with pelvic limbs since 2019.  
Abnormal PE/Chem/CBC/UA Results: Ambulatory x 4 with mild delay CP right > left

**SPECIES**

Canine

**COMPUTED TOMOGRAPHIC STUDY OF THE SPINE**

Pre/post contrast studies provided for review.

**BREED**

Yorkshire Terrier

**COMPUTED TOMOGRAPHIC FINDINGS**

At the level of L2/3 there is a collapsed intervertebral disc space noted with significant erosion of the cranial end plate of L3. A severe, calcified disc herniation is noted with severe compression of the spinal cord. The herniated disc material is located at the level of the disc space and lies broad-based medial to right- and left-lateral and -foraminal. Mild ventral spondylosis and sclerosis of the end plates is recognized.

**SEX**

Intact Male

The presented bony structures of the spine are unremarkable apart from that with an inconspicuous and harmonic thoracolumbar- and lumbosacral transition.

**AGE**

8.5 Years

Paravertebral soft tissues are bilaterally symmetrical, especially the course of the femoral and sciatic nerves is inconspicuous. Unilateral atrophy of the paraspinal and/or pelvic musculature is not noted.

**INTERPRETED BY**

Sebastian Jawinski,  
German Board  
Certified Vet  
Specialist in  
Diagnostic Imaging

**COMPUTED TOMOGRAPHIC DIAGNOSIS**

- Severe disc herniation L2/3 with severe compression of the spinal cord
- Erosive/lytic changes of the cranial end plate of L3

**HOSPITAL NAME**

Mobile Pet Imaging

**INTERPRETATION OF THE FINDINGS & FURTHER RECOMMENDATIONS**

The sclerosis and the ventral spondylosis of L2/3 indicates a chronic issue. Collapse of the disc and (chronic) herniation may have been triggered by that. There is severe compression of the spinal cord recognized. Foraminal compression of the spinal nerves is assumed since the herniation shows lateral/para-spinal extend on both sides. The erosive/lytic changes of the cranial end plate reveal an active osteochondrosis as seen with spondylitis. Small impression fractures are possible. Neoplasia is unlikely.

**REFERRING VET**

Meaux

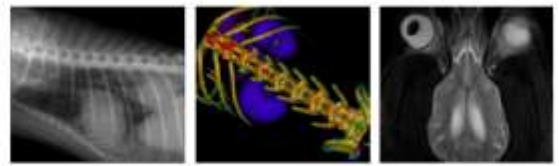
**INVOICE**

47335

CT findings must be correlated with the clinical presentation and decompressive surgery with biopsy and microbiological testing should be considered (hemilaminectomy, approach from the right). Surgery of chronic herniations may have a bad prognosis.

**DATE**

9-2-21



**PATIENT**

Frankie Walsh

**SPECIES**

Canine

**BREED**

Yorkshire Terrier

**SEX**

Intact Male

**AGE**

8.5 Years

**INTERPRETED BY**

Sebastian Jawinski,  
German Board  
Certified Vet  
Specialist in  
Diagnostic Imaging

**HOSPITAL NAME**

Mobile Pet Imaging

**REFERRING VET**

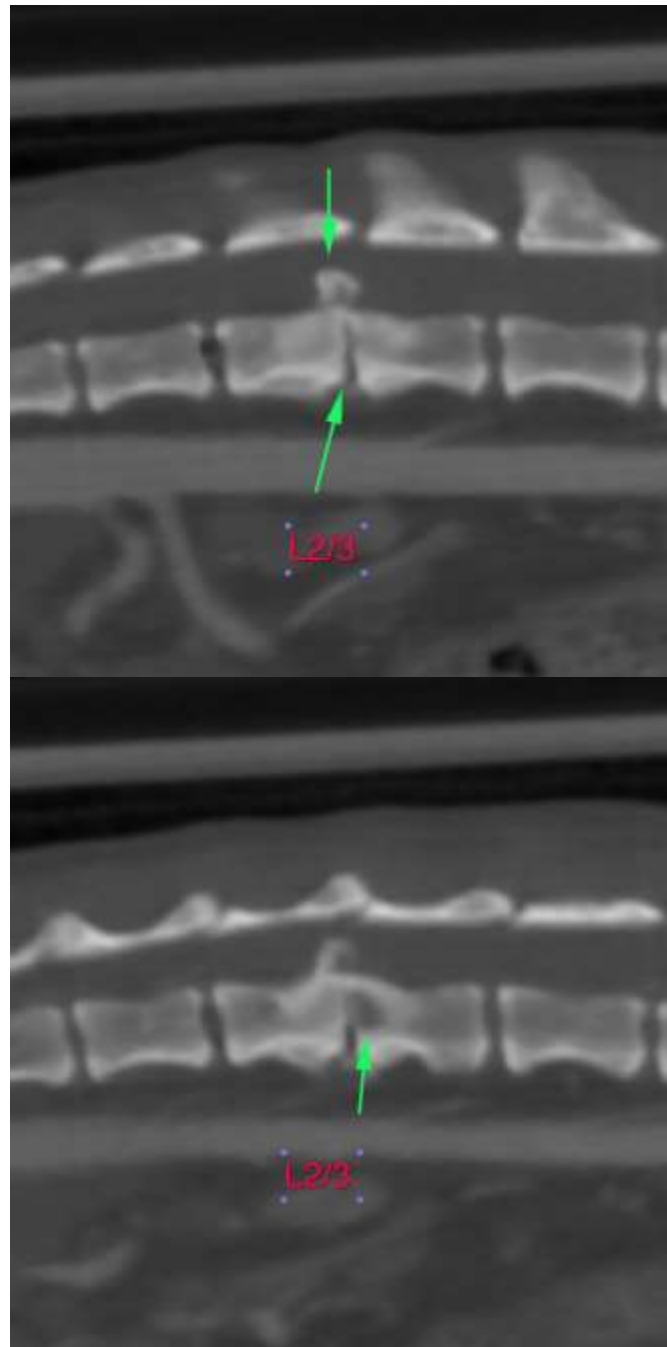
Meaux

**INVOICE**

47335

**DATE**

9-2-21





**PATIENT**

Frankie Walsh

**SPECIES**

Canine

**BREED**

Yorkshire Terrier

**SEX**

Intact Male

**AGE**

8.5 Years

**INTERPRETED BY**

Sebastian Jawinski,  
German Board  
Certified Vet  
Specialist in  
Diagnostic Imaging

**HOSPITAL NAME**

Mobile Pet Imaging

**REFERRING VET**

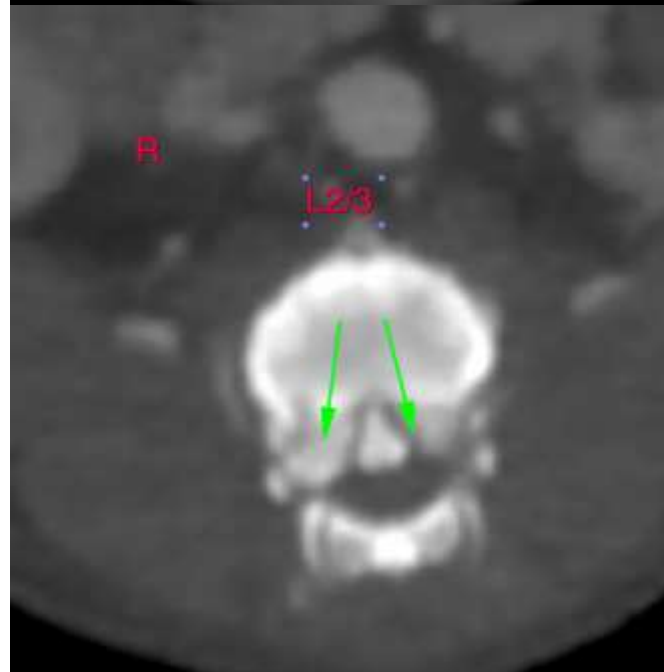
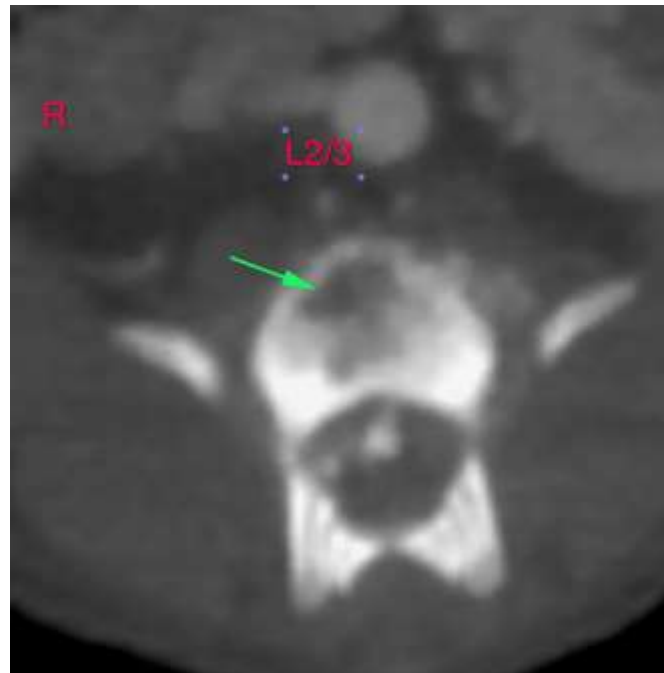
Meaux

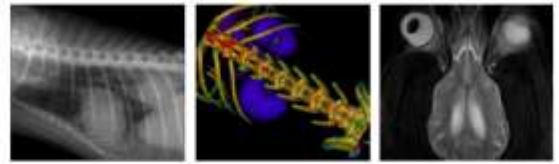
**INVOICE**

47335

**DATE**

9-2-21





**PATIENT**

Frankie Walsh

The information and recommendations provided are based on the images presented by the referring veterinarian. No evaluation can be communicated regarding pathology that was not visible in the image/video clips provided.

**SPECIES**

Canine

Thank you for this referral. If the clinical or image interpretation does not parallel your findings or if I can be of any further assistance, please contact me.

**Sebastian Jawinski, German Board Certified Vet Specialist in Diagnostic Imaging**  
Sebastian.Jawinski@sonopath.com

**BREED**

Yorkshire Terrier

**SEX**

Intact Male

**AGE**

8.5 Years

**INTERPRETED BY**

Sebastian Jawinski,  
German Board  
Certified Vet  
Specialist in  
Diagnostic Imaging

**HOSPITAL NAME**

Mobile Pet Imaging

**REFERRING VET**

Meaux

**INVOICE**

47335

**DATE**

9-2-21